

# Nasopharyngeal Angiofibroma: Case Report With Role of Radiodiagnostic Procedures

Digvijay Suresh Motghare<sup>1</sup>, Kaustubh Sansare<sup>2</sup>, Freny Karjodkar<sup>3</sup>, Amaresh Chandra Dora<sup>1</sup>

<sup>1</sup>Postgraduate Student, <sup>2</sup>Associate Professor, <sup>3</sup>HOD and Professor, Department of Oral Medicine and Radiology, NHDC, Mumbai, India

**Corresponding author:** Dr. Digvijay Suresh Motghare (Postgraduate student, Department of Oral Medicine and Radiology, NHDC, Mumbai).

**How to cite this article:** Digvijay Suresh Motghare, Kaustubh Sansare, Freny Karjodkar, Amaresh Chandra Dora. Nasopharyngeal angiofibroma: case report with role of radiodiagnostic procedures. *International Journal of Contemporary Medicine Surgery and Radiology*. 2016;1(1):25-28.

## A B S T R A C T

**Introduction:** Juvenile angiofibroma is a relatively rare lesion that most commonly affects the nasal and paranasal cavity of young individuals, with maximal prevalence in males and with well characterised clinico-radiological features. Juvenile nasopharyngeal angiofibroma is a locally aggressive benign vascular neoplasm, composed of vasogenic and myofibroblastic elements, accounts for 0.05–0.5% of all the head and neck neoplasms. There are very few case reports of nasopharyngeal angiofibroma involving the oral cavity.

**Case Report:** Here is a case of 17 year old patient who reported with a large firm swelling on left side of face with recurrent epistaxis and headache. Magnetic resonance angiography revealed a large lobulated enhancing soft tissue mass, which was hypointense on T1weighted image and heterogeneously hyperintense on T2weighted image causing expansion of pterygopalatine fossa and sphenopalatine foramen with extension into the sphenoid sinus, ethmoid air cells, left nasal cavity, left infratemporal fossa and left maxillary sinus with remodeling of left zygomatic arch and part of body and ramus of mandible.

**Conclusion:** The diagnosis at an early stage is important because it is associated with high risk of morbidity, but advances in imaging, and surgical methods of treatment have changed the sites associated with high risk of morbidity.

**Keywords:** Nasopharyngeal Angiofibroma, Radiodiagnostic Procedures

## INTRODUCTION

Vascular lesions of the head and neck represent a challenging pathologic subset for the clinician and the radiologist. Juvenile angiofibroma (JA) is an uncommon benign vascular tumour almost exclusively occurring in the nasal and paranasal cavities of adolescent males,<sup>1,2</sup> which constitutes approximately 0.05% of all tumours of the maxillofacial area.<sup>3</sup> It is characterised morphologically by irregular, proliferating vascular channels within a fibrous stroma, which consists of plump, spindle or stellate cells. It has a peculiar propensity for local extension into the adjacent tissues that often precludes complete surgical resection and likely is responsible for tumour persistence and recurrences in 21–34% of the affected patients.<sup>3,4</sup> Topographically, this tumour frequently originates in the postero-lateral wall of the nasal cavity, close to the superior margin of the sphenopalatine foramen. Subsequently, JA may cause bone erosion and displacement of adjacent structures, thus involving the nasopharynx, paranasal, ethmoidal and maxillary sinuses, orbit and skull base, with possible intracranial extension.<sup>3-5</sup> Vascular lesions of the head and neck represent a

challenging pathologic subset for the clinician and the radiologist. Ultrasonography is an appropriate initial screening modality, particularly in superficial lesions.<sup>6</sup> Ultrasonography can help to identify rudimentary characteristics of the lesion, delineate lesion depth, characterize cystic/solid spaces, and identify the lesion's flow characteristics. MRI is often used for further characterization because it is the best modality for delineating lesion extent and determining the involvement of soft tissue structures.<sup>6,8</sup> When available, dynamic magnetic resonance angiography (such as 4DTRAK) can noninvasively determine the flow pattern within a lesion and thereby help in the diagnosis.<sup>9</sup> CT can also provide a wealth of diagnostic information and is particularly valuable in determining bony involvement, vascularity, and in evaluating for the presence of phleboliths (also identified on plain radiography). However, CT use should follow the “as low as reasonably achievable” principles to minimize radiation exposure, especially in pediatric patients. Catheter angiography plays a limited role and is mainly employed when embolization therapy is a consideration. In many cases, characterization of the intralésional components and anatomic location allows

for a definitive diagnosis.

Here, we are reporting a case of JNA in a 15 year old male presenting as an extraoral facial swelling with stage IV and reviews the pathogenesis and role of imaging in the diagnosis of the tumour.

### CASE REPORT

A 17 year old male patient reported to the Outpatient Department of NHDC Mumbai with the chief complaint of swelling on the left side of the face since 2 years that had rapidly increased in size since last 4–5 months. It was associated with occasional intermittent, spontaneous pain and continuous headache which aggravated on bending, with frequent epistaxis from the left nostril with feeling of stuffiness of nose and nasal discharge. The medical history was not significant. Physical examination along with cranial nerve examination did not reveal any abnormality. Extraoral examination [Figure 1] was suggestive of a lobular swelling on the left side of the face extending from infraorbital margin to the lower border of mandible superoinferiorly and from ala of nose and corner of the mouth to tragus of ear and ramus of mandible anteroposteriorly approximately 7 cm × 8 cm in size. The swelling was smooth surfaced with well defined margins and resilient in consistency. It was compressible, pulsatile, and tender on palpation. The swelling reduced in size on opening the mouth and on clenching, swelling became more prominent adjacent to ramus of mandible. The mouth opening was reduced with deviation toward left on opening. The left submandibular lymph nodes were found to be enlarged, tender and mobile on palpation.

#### Intraoral findings

The buccal mucosa on the right side was swollen and lobulated extending from the corner of the mouth to the ramus of mandible with indentations on its surface. Obliteration of buccal vestibule with crowding of maxillary anterior teeth. (figure 2) Routine hematological investigations were found to be within the normal limits. Fine needle aspiration of the swelling and the lymph node was performed, which revealed only blood.

plain coronal CT scan of paranasal sinuses was performed was performed on 64 slice MDCT scanner with thin sections with multiplaner reconstruction, an ill defined 9.3x9.5x11 cm (MLXAPXSI) sized, lobulated intensely and heterogeneously, enhancing mass with its epicentre in the region of left pterygopaltine fossa with multiple nonenhancing hypodense areas within severely widening the left pterygopaltine fossa, causing posterior displacement of base and splaying, rarefaction of medial and lateral pterygoid plates. (figure 3,4)

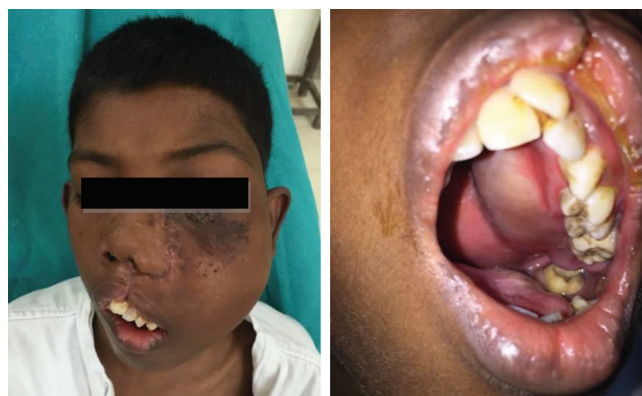Pre and past contrast multiplanar MRI of the PNS and brain done on 3.0 Tesla machine was performed using T1 weighed gradient echo, T2 weighed fast spin echo and fast FLAIR segments.

An ill defined 9.3x9.5x11 cm (MLXAPXSI) sized, lobulated, intensity and heterogeneously enhancing mass with its epicentre in the region of pterygopaltine fossa with multiple nonenhancing hypointense areas (s/o necrosis) within which is heterogeneously hyperintense on T1 images with multiple areas of flow void and cystic spaces within 72 images (figure 5, 6)

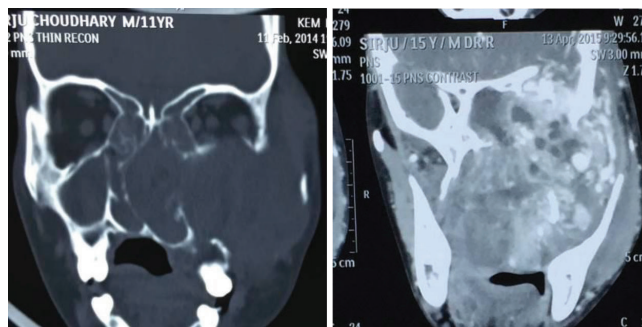
Based on history, clinical presentation, CT and MRI findings, the lesion was finally diagnosed as nasopharyngeal angiofibroma. Patient was referred to the Department of Neurosurgery for further management where it was planned to carry out the initial embolization of the lesion to be followed by surgery.

### DISCUSSION

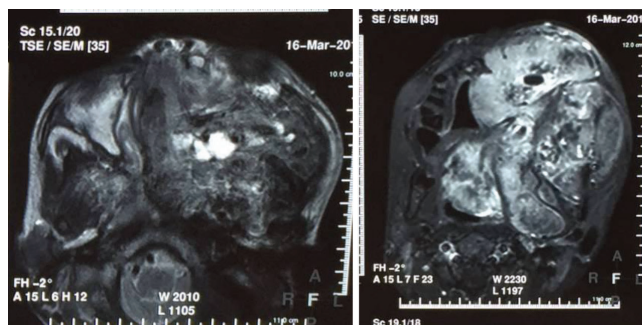
JA is an uncommon benign lesion accounting for 0.05% of all head and neck tumours<sup>3</sup>, and almost exclusively affecting



**Figure-1:** Extraoral diffuse swelling on the left side of face; **Figure-2:** Intraoral examination



**Figure-3:** Plain coronal CT scan; **Figure-4:** Plain coronal CT scan



**Figure-5:** Pre contrast multiplanar MRI; **Figure-6:** Post contrast multiplanar MRI

adolescent males (median age: 15.3 years).<sup>9,10</sup> This lesion has been variably named in the literature until relatively recently when Friedberg defined it as “angiofibroma”. It usually affects the posterior nasal cavity, in close relationship with the sphenopalatine foramen,<sup>3,5,7</sup> even if some authors maintain its origin in the pterygopalatine fossa<sup>10</sup>, with subsequent spread through natural foramina and fissures to the adjacent structures.<sup>3,5</sup> Nasal obstruction and recurrent epistaxis are the early symptoms that can suggest the diagnosis

of JA when present in an adolescent boy.<sup>10</sup> Additional symptoms are facial swelling and bulging, headache, otalgia, hearing loss, eyelid edema, proptosis, visual changes, sinusitis, meningitis.<sup>5,7</sup> These symptoms, in association with typical radiological findings, are very useful for a precise clinical diagnosis and subsequent therapy. Imaging studies are extremely important in the pre-operative work-up of JA: CT and MR are usually employed to define tumour site and extension, especially when involvement of the skull base or intracranial extension may be foreseen on a clinical base. Angiography is used to define tumour blood supply, vascular architecture and venous drainage of the tumour. Nowadays, pre-operative embolisation can be used to decrease the need of blood transfusion and to facilitate tumour surgical resection/ablation. JAs with primary intra-oral presentation are exceedingly rare, three such cases having been reported so far, including the current one.<sup>5,7</sup> In view of its rarity, many other lesions may enter in the differential diagnosis, including primary bone lesions (fibrous dysplasia and ossifying fibroma, cherubism, giant cell granuloma, osteosarcoma), odontogenic neoplasms (ameloblastoma, odontogenic fibroma) or gingival hyperplastic processes (peripheral giant cell granuloma, drug-induced hyperplasia, fibromatosis). Both clinical examination and radiological investigations may prove of little value to achieve a definitive diagnosis and the occurrence of rapid growth or bone erosion/destruction may lead to consider malignant neoplasms in the differential. For such reasons, pre-operative diagnostic biopsies are recommended to avoid unnecessary overtreatments. Though originally described as a locally aggressive benign tumour and classified among “miscellaneous tumours” in the recent WHO classification of soft tissue tumours, it remains unclear whether JA should be considered a true neoplasm or a hamartoma (vascular malformation). Most authors consider JA as a true neoplasm, both for the direct evidence of expression of androgen receptors in stromal and endothelial cell nuclei, and for the localisation of activated transforming growth factor beta 1 (TGF-beta 1) to the fibroblasts and endothelial cells within the neoplasm, which can play an important role in stromal cell proliferation and angiogenesis. Others have interpreted JA as hemangioma, hyperplastic lesion, overgrowth of

paraganglionic tissue, hamartoma simulating the erectile tissue of the penis, fibromatosis,<sup>2</sup> teratoma<sup>10</sup> or congenital deformity. According to Beham et al.,<sup>9</sup> the unusual vascular growth pattern and the considerable size and architectural variations are useful features for adequate differential diagnosis with other vascular lesions and are indicative to consider JA as a “vascular malformation” or as a “vasoproliferative malformation”. Similarly, Schick et al. defined angiofibroma as a vascular malformation and stressed that the vascular component of JA can originate as a consequence of incomplete regression of the first branchial arch artery (vascular atavism). This interpretation would account for the main characteristics of the tumour such as the origin in the postero-lateral nasal cavity and the main blood supply from the maxillary artery. Though we concur with other authors<sup>9</sup>, to consider JA as a vascular malformation, we would like to underline that the same histogenesis has been considered for other benign vascular tumours, such as capillary and cavernous haemangiomas. Persistent outgrowth of such neoplasms may result in extension into adjacent structures and in rare instances this may become a lifethreatening event due to tumour rupture and subsequent haemorrhage. The natural clinical course of JA is rather different as it is capable of true invasion into adjacent structures, possibly due to the peculiar stromal component of this lesion that is consistently different from that of other benign vascular lesions. This may also account for the relatively high incidence of recurrences (21–34% of the patients)<sup>3,4</sup> for JA in comparison with other vascular lesions as deep penetration into adjacent tissues may prevent from complete surgical removal unless wide excision are performed.

## REFERENCES

1. Harma RA. Nasopharyngeal angiofibroma. *Acta Otolaryngol Suppl.* 1958;146:1–76.
2. Dillard DG, Cohen C, Muller S, Del Gaudia J, Reichman O, Parrish B. Immunolocalization of activate transforming growth factor B1 in juvenile nasopharyngeal angiofibroma. *Arch Otolaryngol Head Neck Surg.* 2000;126:723–5.
3. Tewfik TL, Tan AKW, Al Noury K, et al. Juvenile nasopharyngeal angiofibroma. *J Otolaryngol.* 1999;28:145–51.
4. McCombe A, Lund VJ, Howard DJ. Recurrence in juvenile angiofibroma. *Rhinology.* 1990;28:97–102.
5. Antoniadis K, Antoniadis DZ, Antoniadis V. Juvenile angiofibroma: report of a case with intraoral presentation. *Oral Surg Oral Med Oral Pathol.* 2002;94:228–32.
6. Yang WT, Ahuja A, Metreweli C. Sonographic features of head and neck hemangiomas and vascular malformations: review of 23 patients. *J Ultrasound Med.* 1997;16:39–44.
7. Rozylo-Kalinowska I, Brodzisz A, Galkowska E, et al. Application of Doppler ultrasonography in congenital vascular lesions of the head and neck. *Dentomaxillofac Radiol.* 2002;31:2–6.

8. Baker LL, Dillon WP, Hieshima GB, et al. Hemangiomas and vascular malformations of the head and neck: MR characterization. *AJNR Am J Neuroradiol.* 1993;14:307–14.
9. Kabot TE, Goldman ME, Bergman S, Schwartz RD. Juvenile nasopharyngeal angiofibroma: an unusual presentation in the oral cavity. *Oral Surg Oal Med Oral Pathol.* 1985;59:453–7.
10. Bremer JW, Neel HB, DeSanto LW, Jones GC. Angiofibroma: treatment trends in 150 patients during 40 years. *Laryngoscope.* 1986;96:1321–9.

**Source of Support:** Nil; **Conflict of Interest:** None

**Submitted:** 07-10-2016; **Published online:** 17-11-2016