

Temporomandibular Joint Ankylosis- a Case of Double Trouble

Himangi Srivastava¹, Karthik Hegde², Preeti Nair³, Harshakant Gharote⁴, Neha Gupta⁵, Pearl Helena Chand¹

¹Post Graduate Student, ²Reader, ³Professor and Head, ⁴Professor, ⁵Senior Lecturer, Department of Oral Medicine and Radiology, People's College of Dental Sciences, Bhopal, India.

Corresponding author: Dr. Himangi Srivastava, Suchita Girls Hostel, Near Sagar Avenue, Narela bypass road, Bhopal (462021), India.

How to cite this article: Srivastava H, Hegde K, Nair P, Gharote H, Gupta N, Chand PH. Temporomandibular joint ankylosis- a case of double trouble. International Journal of Contemporary Medicine Surgery and Radiology. 2016;1(1):21-24.

ABSTRACT

Introduction: Ankylosis of the temporomandibular joint (TMJ) is the fibrous or bony fusion of the articular components of the joint. The condition presents with limited mandibular opening, facial deformity and difficulty in mastication, speech and oral hygiene maintenance with psychological distress. Trauma, infection, inflammation and systemic diseases are the main etiological factors involved in its causation.

Case report: This case report illustrates a case of a 21 year old male patient with unilateral TMJ fibrous ankylosis associated with ipsilateral coronoid process elongation and the impact this entity has on mandibular growth.

Conclusion: This condition poses functional as well esthetic problem for the patients afflicted with it. Since TMJ ankylosis may go unnoticed for long period of time, early intervention and mobilization is mandatory and can be deterrent to proper growth and function of the mandible.

Keywords: coronoid elongation, antegonial notch, bony fusion, intra-articular ankylosis.

INTRODUCTION

Temporomandibular joint (TMJ) ankylosis also named as the craniomandibular joint (CMJ) ankylosis is a Greek term that means "stiff joint".¹ It is the union of the disc condyle complex to the opposing temporal articular surface.²

The American Academy of Orofacial Pain (AAOP) defines TMJ ankylosis as a restriction of movements due to intracapsular fibrous adhesions, fibrous changes in capsular ligaments (fibrous-ankylosis) and osseous mass formation resulting in the fusion of the articular components (osseous-ankylosis).³

TMJ ankylosis may be classified based on the site (intra articular versus extra articular), type of tissue involved (bony, fibrous or fibro-osseous tissue), degree of fusion (complete versus incomplete) and number of joints affected (unilateral or bilateral).¹ False or pseudo ankylosis is the one with extra articular factors. Topazian proposed a three-stage classification for complete ankylosis: stage I, ankylotic bone limited to the condylar process; stage II, ankylotic bone extending to the sigmoid notch; and stage III, ankylotic bone extending to the coronoid process.⁴

Trauma, infection, inflammation and systemic diseases are purported as the main etiological factors with the first two being the leading causes.^{5,6} Depending on the severity and

age of presentation, the patient manifests with trismus, compromised mandibular growth, facial deformity and malocclusion which may influence esthetics, oral hygiene, mastication and speech leading to psychological distress.³ Here is a case of unilateral fibrous ankylosis with ipsilateral coronoid elongation. Since TMJ ankylosis goes unnoticed for long period of time, early diagnosis and better management can help to reduce morbidity of TMJ ankylosis.

CASE REPORT

A 21 year male patient reported to the Department of Oral Medicine and Radiology with the chief complaint of poor facial esthetics and reduced mouth opening since childhood. He reported that the facial deformity progressed with age. He gave no history of trauma, ear infections or any other systemic illness/ relevant medical history.

Extraoral examination (figure 1) elicited obvious facial asymmetry, convex facial profile, hypoplastic mandible on left side; chin deviated to left side, fullness of left side of the face, flattening of lower one third of face on right side, prominent left antegonial notch and 13 mm interincisal opening. TMJ movements were restricted on either side, more so on the left side. Intraoral examination (figure 2) revealed dental midline shifted to left side, occlusal cant

and posterior cross-bite on left side.

Radiographic investigations included orthopantomogram (OPG) and computer tomography (CT) scan. The orthopantomogram (figure 3) revealed shortened body of mandible, decreased ramus height, deep sigmoid notch, narrow joint space, elongation of coronoid process of mandible and accentuated antegonial notch on the left side. CT images showing the coronal section (figure 4) and 3-D reconstruction (figure 5) revealed thickened bone of glenoid fossa, wide condylar head, elongated coronoid process, shortened body and ramus of mandible and reduced but preserved joint space on the left side, suggestive of fibrous ankylosis. Occlusal canting towards the right side can also be appreciated.

The surgical plan for enhancing mouth opening included interpositional gap arthroplasty with ipsilateral coronoidectomy on the affected side, followed by physiotherapy. For the correction of facial deformity, LeFort I osteotomy with mandibular distraction osteogenesis on the affected side would be the method of choice.

DISCUSSION

Ankylosis of temporomandibular joint (TMJ) is the union of articular surfaces of condyle to that of glenoid fossa which later restricts the mandibular movement. This state could be primarily due to congenital defect or secondary

to infections, trauma, post surgical malunion or systemic conditions like ankylosing spondylitis, rheumatoid arthritis etc.

Based on the anatomic location of involvement in the joint, ankylosis can be either intra articular and extra articular ankylosis. Intraarticular ankylosis is considered when the joint undergoes progressive destruction of the

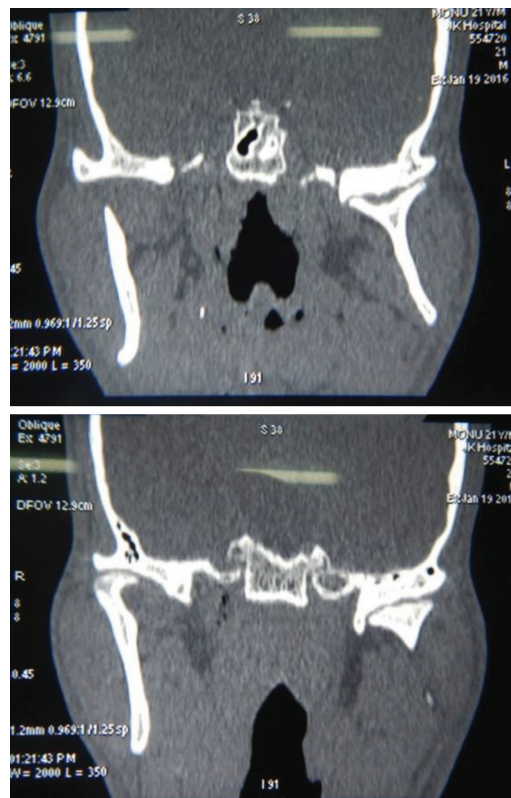


Figure-4: Coronal sections of CT scan showing reduced left joint space

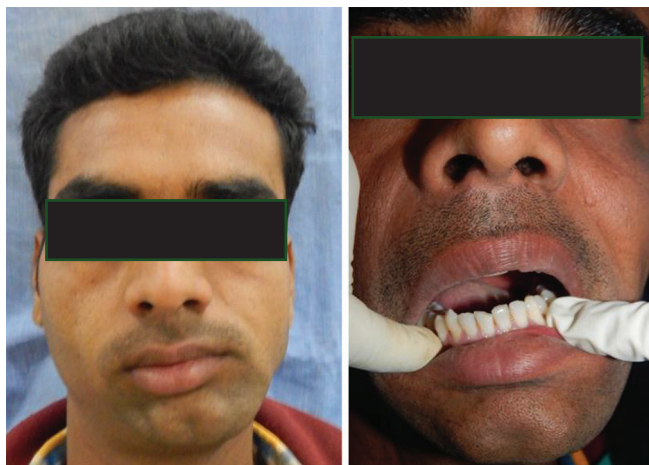

Figure-1: Extraoral profile image; **Figure-2:** Intraoral image

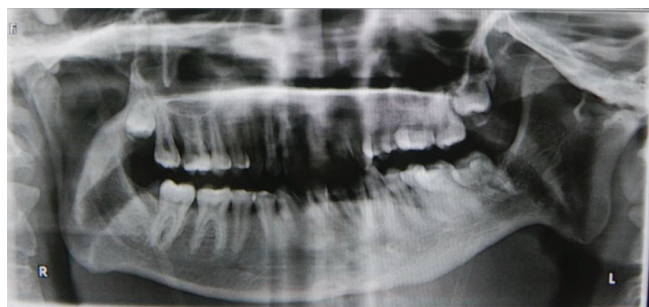

Figure-3: Panoramic image showing shortened mandible, deep antegonial notch, reduced joint space and elongated coronoid on the left side.

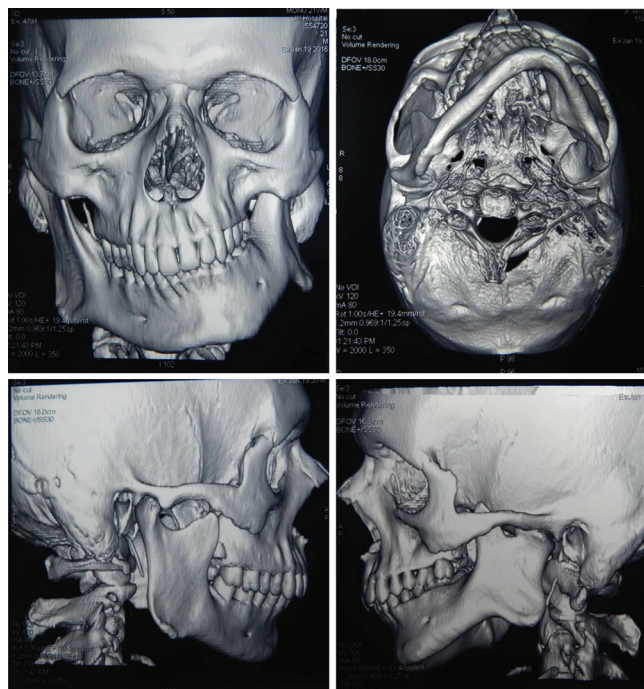


Figure-5: 3-D reconstruction images of CT scan showing shortened mandible and elongated coronoid on the left side

meniscus with degeneration of the glenoid fossa and condyles with subsequent reduction of the joint spaces. Such an ankylosis basically is of fibrous type. Bony union results when ossification in the scar occurs in chronic cases. Splinting of the TMJ by fibrous or bony tissue external to the joint proper leads to extraarticular ankylosis, as in the case of infection of the surrounding bone or extensive tissue destruction, mechanical obstruction (eg, zygomatic arch and condylar fracture, adhesions or hypertrophy of the coronoid process), muscle spasm, myositis ossificans, scar contracture following thermal injury or tumor of the condyle or coronoid process.⁴

Causal factors implicated for this ailment comprise of trauma, infection, inflammation and systemic diseases. Inflammation may result from local neighboring infection such as otitis media, mastoiditis, osteomyelitis of mandible or from hematogenous spread from tuberculosis, gonorrhea, scarlet fever. Systemic diseases include rheumatoid arthritis, ankylosing spondylitis, psoriasis, reiter's syndrome, sickle cell anemia, fibrodysplasia ossificans progressive, paget's disease and pseudohypoparathyroidism.^{7,8} Numerous studies have reiterated trauma as the predominant cause of ankylosis.⁹ However, advances in management of condylar fracture and infection has led to waning in incidence of ankylosis in the developed world.¹⁰

Ajike and Omisakin retrospectively reviewed cases within a span of 9 years and obtained 26 ankylosis cases, with the mean age at presentation as 14.9 years and female predilection.¹⁰ Bello et al obtained 23 ankylosis patients over a period of 5 years, retrospectively, and found male gender preponderance, 20 years as the mean age and 6.7 mm as the mean mouth opening among the patients.¹¹ Hameed et al in his study of 96 patients of TMJ ankylosis found the gender distribution to be 60.4% males and 39.6% females.⁶ Hossain et al, in his study of 60 ankylosis patients (over a one year period) found female gender and 11-20 years age group to be predominantly involved.¹² In a population-based study, Gupta et al found the overall prevalence of TMJ ankylosis in Lucknow to be 0.46 per 1,000 children, with female preponderance and the most prevalent age group was 11-15 years.⁹ In all the above studies, trauma was the most frequent etiology.

In the present case, no definite etiology could be established but presence of missed trauma can be considered because the traumatic lesions of the TMJ often are overlooked as they can apparently occur with relatively little pain. Also time lapse from the time of trauma and lack of information given by patients hampers accurate designation of etiology. Hossain et al reported that 3.3% cases of TMJ ankylosis did not have a definite etiology.¹²

TMJ ankylosis accompanied with ipsilateral coronoid elongation was found in the present case. This feature has also been reported in other studies and case reports.^{5,6} The hypotheses suggests that the reactive elongation

of coronoid process takes place as a consequence of hyperactive temporalis muscle due to restricted condylar translation which occurs in ankylosis.¹³

Various theories have been put forward to elucidate the pathogenesis of ankylosis. Trauma can result in an intra-articular hematoma leading to fibrosis, excess bone formation, and ultimately to limitation of joint movement. Ferretti et al. suggested that dislocated condylar head fracture generates a cavity that is consequently filled by blood forming a large hematoma which, due to disruption of the periarticular anatomic boundaries reaches to extracapsular sites, and hence evades any impediment that the articular disc may cause. Ensuing this, tumour growth factor (TGF) and bone morphogenic proteins (BMP) are expressed at the fracture site, which activate osteoblasts and culminate in ossification when the hematoma is populated by endosseous vessels (vascularisation of a hematoma is important for its ossification) and there is a sufficient degree of immobility. Vigorous mobilisation after injury is significant in preventing the complication of ankylosis after condylar fracture.¹⁴ In 1982, Rowe and in 2008, He et al. suggested that sagittal fracture of the condyle plays role in ankylosis.⁸ The fractured lateral fragment gets displaced superiorly over the glenoid fossa, with associated displacement of the articular disc, which may be responsible for ankylosis.

On the contrary, Oztan et al. concluded that trauma leading to hemorrhage in the joint space may not give rise to ankylosis as it does not always progress to bone formation. The concept of meniscus playing a role in genesis of ankylosis advocates that an intact disc may act as a physical impediment to prevent fusion of the condyle with the glenoid fossa. In the event of damage to the disc, the condyle and glenoid may fuse if the bony surfaces are also damaged and there is a hematoma between them. But this does not explain how, ankylosis still occurs, particularly in children, after condylar head fracture even though the meniscus is present and undamaged. Lately, it has been postulated that distraction osteogenesis caused by traction of the lateral pterygoid muscle on the bone after sagittal fracture of the mandibular condyle may be an important feature in the development of traumatic ankylosis of the TMJ. However, the muscle will tend to pull the bony fragment in a medial and upward direction away from the condylar region (because the attachment of the muscle is at the neck of the condyle and not at the head), so its role in ankylosis is not convincing.⁸

Alternatively, it has been proposed that ankylosis may be as a consequence of inappropriate tissue differentiation after fracture similar to the events of fracture healing.⁷ However, this cannot be the case as ankylosis involves the fusion of two different bony surfaces (condyle with cancellous, and glenoid with compact bone).

Recently, protein energy malnutrition has been purported as a predisposing factor for ankylosis. It has been reported

in rats that malnutrition results in impaired callus formation, as well as fibrous ankylosis on healing of a displaced condylar process.¹⁵

CONCLUSION

Temporomandibular Joint (TMJ) ankylosis is one of the most frequent pathologies concerning the facial skeleton. Patients afflicted with this condition bear problems ranging from limited mouth opening to psychological distress. It poses functional as well as esthetic problem. When it occurs at an early age, it may hamper the normal development of the mandible. Long standing fibrous ankylosis may progress to bony ankylosis. Since TMJ ankylosis goes unnoticed for long period of time, early intervention and mobilization is mandatory and can be deterrent to proper growth and function of the mandible.

REFERENCES

1. Butt FM, Guthua SW, Kegereki EM. Preliminary Outcome of Case Series of the Management of Unilateral and Bilateral Craniomandibular Ankylosis in Kenya- An Ongoing Prospective Study. *Open Journal of Stomatology*. 2015;5:227-33.
2. Shanmugavadivel G, Vasanthakumari A, Sankar S. Unilateral temporomandibular joint ankylosis- a case report. *Journal of Dental and Medical Sciences*. 2016;15:101-3.
3. Cunha CO, Pinto LM, de Mendonça LM, Saldanha AD, Conti AC, Conti PC. Bilateral asymptomatic fibrous-ankylosis of the temporomandibular joint associated with rheumatoid arthritis: a case report. *Braz Dent J*. 2012;23:779-82.
4. August M, Troulis MJ, Kaban LB. Hypomobility and Hypermobility Disorders of the Temporomandibular Joint. In: Miloro M, editor. *Peterson's Principles of Oral and Maxillofacial Surgery*. 2nd ed. Hamilton, London. BC Decker Inc; 2004.
5. Rishiraj B, McFadden LR. Treatment of temporomandibular joint ankylosis: a case report. *J Can Dent Assoc*. 2001;67:659-63.
6. Hameed H, Alamgeer, Shad S, Din Q. Etiology, clinical and radiographic features of temporomandibular joint ankylosis. *Pak Oral Dental Journal*. 2013;33:26-30.
7. Güven O. A clinical study on temporomandibular joint ankylosis. *Auris Nasus Larynx*. 2000;27:27-33.
8. Arakeri G, Kusanale A, Zaki GA, Brennan PA. Pathogenesis of post-traumatic ankylosis of the temporomandibular joint: a critical review. *Br J Oral Maxillofac Surg*. 2012;50:8-12.
9. Gupta VK, Mehrotra D, Malhotra S, Kumar S, Agarwal GG, Pal US. An epidemiological study of temporomandibular joint ankylosis. *Natl J Maxillofac Surg*. 2012;3:25-30.
10. Ajike SO, Omisakin OO. Temporomandibular joint ankylosis in a Nigerian teaching hospital. *West Indian Med J*. 2011;60:172-6.
11. Bello SA, Aluko Olokun B, Olaitan AA, Ajike SO. Aetiology and presentation of ankylosis of the temporomandibular joint: report of 23 cases from Abuja,

Nigeria. *Br J Oral Maxillofac Surg*. 2012;50:80-4.

12. Hossain MA, Shah SA, Biswas RS. Frequency of temporomandibular joint ankylosis in various age groups with reference to etiology. *Chattagram Maa-O-Shishu Hospital Medical College Journal*. 2014;13:17-20.
13. Isberg AM, McNamara JA, Carlson DS, Isacson G. Coronoid process elongation in rhesus monkeys (*Macaca mulatta*) after experimentally induced mandibular hypomobility. A cephalometric and histologic study. *Oral Surg Oral Med Oral Pathol*. 1990;70:704-10.
14. Deckers MM, van Bezooijen RL, van der Horst G, Hoogendam J, van Der Bent C, Papapoulos SE, Löwik CW. Bone morphogenetic proteins stimulate angiogenesis through osteoblast-derived vascular endothelial growth factor A. *Endocrinology*. 2002;143:1545-53.
15. Rodrigues L, Corrêa L, Luz JG. Healing of displaced condylar process fracture in rats submitted to protein undernutrition. *J Craniomaxillofac Surg*. 2011;39:73-8.

Source of Support: Nil; **Conflict of Interest:** None

Submitted: 06-10-2016; **Published online:** 17-11-2016