ORIGINAL RESEARCH ARTICLE

# Role of MDCT and USG in Evaluating Retroperitoneal Masses

**Kumar Ashok Charan[1], Meenakshi Parthasarathy[2], Parthasarathy K R[3], Mythri Nag[4], Mehathab M Bava[5]**

[1]Assistant professor, Department of Radiodiagnosis, Dr B R Ambedkar Medical College, Bengaluru, [2]Professor & Head, Department of Anatomy, Bowring & Ladycurzon Medical College, Bengaluru, [3]Professor and Head, Department of Radiodiagnosis, SSIMS & RC, Davangere, [4]Junior Resident, Department of Radiodiagnosis, SSIMS & RC, Davangere, [5]Junior resident, Department of Radiodiagnosis, SSIMS & RC, Davangere, India

**Corresponding author:** Dr Parthasarathy K R, Professor& Head, Department of Radiodiagnosis, SSIMS & RC, Davangere, Karnataka 577004, India

**DOI:** http://dx.doi.org/10.21276/ijcmsr.2021.6.1.11

**How to cite this article:** Kumar Ashok Charan, Meenakshi Parthasarathy, Parthasarathy K R, Mythri Nag, Mehathab M Bava. Role of MDCT and USG in evaluating retroperitoneal masses. International Journal of Contemporary Medicine Surgery and Radiology. 2021;6(1):A54-A58.

## ABSTRACT

**Introduction:** Acute abdomen is caused by a wide variety of conditions. Masses arising from the retro peritoneum are widely classified into Primary retroperitoneal masses and masses arising from the retroperitoneal organs. Masses can be either benign or malignant Diagnostic imaging is plays a vital role in the work-up of patients with acute abdomen. Ultrasound (USG) and computed tomography (CT) are both frequently used along with clinical and laboratory evaluation. Our study aimed to compare the role of USG in the characterization of retroperitoneal masses in comparison with MDCT.

**Material and methods:** This was a descriptive study in a department of Radiodiagnosis. This study was conducted on patients presenting with signs and symptoms of retroperitoneal masses and was evaluated by both USG and MDCT. Ultrasound characteristics like size, appearance, echo texture, vascularity and other findings were studied. The findings were then compared with the findings of MDCT. A total of 36 patients were included in the study.

**Results:** USG has the sensitivity of 77% and accuracy of 78% in the identification and characterization of the retroperitoneal masses compared to that of MDCT. USG and CT have 77% and 100% sensitivity respectively in evaluation of retroperitoneal masses.

**Conclusion:** In view of these findings, we recommend USG as the primary tool for evaluating retroperitoneal lesions and CT for confirmation and for evaluating the complete extent of the lesion.

**Keywords:** MDCT, USG, Retroperitoneal Masses

## INTRODUCTION

The majority of retroperitoneal masses are found incidentally as a result of the use of MDCT, USG, and MRI.[1] Therefore, the proper characterization of the masses is essential so that appropriate management is instituted.[2] USG is often the initial imaging modality of choice for an abdominal mass.[3] But the USG images are often obscured by fat, ribs, bowel gas, lung bases and muscle planes. It is also dependent on the skill of the operator.[4] MDCT has ionizing radiation and is costlier than USG. It is reserved in cases with insufficient USG findings or for diagnosing lesions not imaged on USG due to overlying bowel gas and body habitus.[5] With modern MDCT equipment, the diagnosis of most of retroperitoneal masses is usually straightforward and accurate. On the other hand, MRI can be used to diagnose the lesions which are not picked up by USG or MDCT.[6] It also lacks ionizing radiation and has cross-sectional and multiplanar capability similar to that of USG and MDCT.[7] The current study aimed to evaluate the usefulness of these modalities to characterize the retroperitoneal masses appropriate for the diagnostic need and socioeconomic situation.

## MATERIAL AND METHODS

This prospective comparative study was carried out on patients of Department of Radio-diagnosis at SSIMS and RC, Davangere, Karnataka from November 2018 to November 2019. Total 36 adult subjects (both male and females) of aged ≥ 18 years were for in this study.

Study was done on 36 patients, in tertiary care teaching hospital;in Department of Radio-diagnosis at SSIMS and RC, Davangere, Karnataka from November 2018 to November 2019.

**Sample size calculation:** Convenient sampling method was used for the data collection. A total of 36 patients were included in the study.

**Subjects & selection method**: The study population was drawn from patients with the signs and symptoms of retroperitoneal masses from November 2018 to November 2019. The variables encountered in this study like age, sex, organ of origin, size, appearance, echotexture and vascularity are categorical and were presented as percentages. Diagnostic validity of both USG and MDCT for diagnosing the retroperitoneal masses was assessed using sensitivity,



ISSN (Online): 2565-4810; (Print): 2565-4802 | ICV 2019: 98.48 |

specificity, positive and negative values against HPE findings where ever necessary.

**Inclusion criteria**

1. All patients who present with retroperitoneal masses [from kidneys, ureters, adrenals, duodenum, pancreas, abdominal aorta, caecum, anterior and posterior pararenal space, perirenal space and retroperitoneal lymph nodes(both solid and cystic) referred to the Department of Radio diagnosis.
2. Retroperitoneal masses that were detected incidentally in USG and who were further evaluated with MDCT.

**Exclusion criteria**

1. Patients with allergy to iodinated contrast media.
2. Patients with renal insufficiency.
3. Patients in whom ionizing radiation is contraindicated like proved pregnancy/suspected pregnancy/ elevated renal values were excluded.
4. Patients with known benign findings like renal calculi and simple renal cysts.

**Procedure methodology**

After written informed consent was obtained, a well-designed proforma was used to collect the data of the recruited patients. The proforma included patients with the signs and symptoms of retroperitoneal masses were included in the study. The patients in whom, masses like complex renal cysts were found during imaging for other pathologies were also included.

USG was done using GE LOGIC ultrasound machine in longitudinal and transverse directions covering all the areas of interest. Both low frequency curvilinear (4 – 6Hz) and high frequency linear (7 – 12 Hz) probes were used. Patients were also scanned in prone and lateral positions. Graded compression technique was utilized with exerting gentle compression to reduce the focal distance of high frequency transducer, but also displaces gas in the bowel loops which produces artifacts and precisely locates the region of pathology by maximal tenderness if present. Location, organ of origin, characteristics of mass like size, appearance and echotexture. This was followed by color Doppler examination to know the vascularity of the masses. Findings like metastasis, lymphnodal involvement and infiltration to surrounding structures were also studied.

MDCT scan was done using 128 slice GE revolution machine. Both plain and contrast study was done. Images were taken with a collimation of 1- 3mm.Precontrast images were obtained to assess the presence of calcification or ossification, macroscopic fat, hemorrhage and cystic or necrotic changes. Ultravist (Iopromide) was used as a contrast medium and the dose was calculated according to the body weight (1.5 ml per kg body weight). Arterial phase enhanced images were obtained to characterize hypervascular retroperitoneal lesions such as paraganglioma. Delayed phase or excretory phase enhanced image were useful for retroperitoneal disease that communicated with the urothelial tract.[6] Characteristics like size, appearance, echotexture, metastasis, lymphnodal involvement and infiltration to surrounding structures were studied. In addition, the enhancement pattern of the mass was also studied.

Technical specifications for MDCT:
Scanner type: Multidetector row scanner.
KVp: 120
mAs: 150-300

The records of 36 patients under the study were maintained. All the data from patient's name, age, sex, hospital number, USG findings and MDCT findings were collected and data was entered in Microsoft excel sheet and SPSS V24.

## STATISTICAL ANALYSIS

Data was entered in Microsoft excel sheet and SPSS V24 software. The variables that were encountered like age, sex, organ of origin, size, appearance, echotexture and vascularity are categorical and were presented as percentages. Diagnostic validity of both USG and CT for diagnosing the retroperitoneal masses was assessed using sensitivity, specificity, positive and negative values against HPE findings wherever necessary.

## RESULTS

**Age distribution of patient (n = 36):** A total number of 36 participants were included in the analysis. The mean age of patient population was 50.4 years. Distribution according to the symptoms: Of the 36 cases, majority of patients 11 patients(30%) presented with abdominal pain and vomiting, followed by loss of appetite(19%) and weight loss(15%). 15% of the findings were incidental. Few patients complained of fullness and lump in the abdomen (7%). 6% of patients presented with trauma. Distribution according to the organ of origin: Majority of the cases had kidney as the organ of origin (38%) followed by the adrenals(23%) and the pancreas(14%). 4 cases were seen arising from the aorta, 3 cases from psoas muscle and 1 cases from caecum.

**Characterization of the masses:** Of the 36 cases, only 28 cases were identified on USG. Characterization was done for the 28 cases that were detected.

**Assessment of the size of the masses:** USG: 21 cases had a size ranging from 2-5cm. Only 4 cases which were <2cm were detected on ultrasound. 2 cases were measuring 5-8cm and 1 case was >8cm.MDCT: Majority of the masses (58%) were 2-5cm in size, 2 cases were measuring 5-8cm and 1 case was >8cm. 32% of cases were up to 2cm of size detected on MDCT.

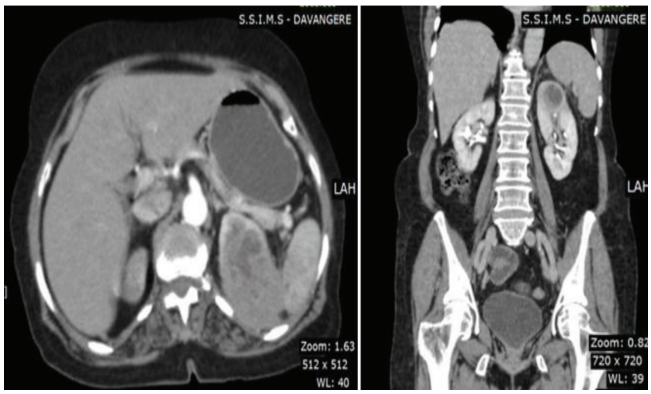


**Case-1:** Renal cell carcinoma


ISSN (Online): 2565-4810; (Print): 2565-4802 | ICV 2019: 98.48 |

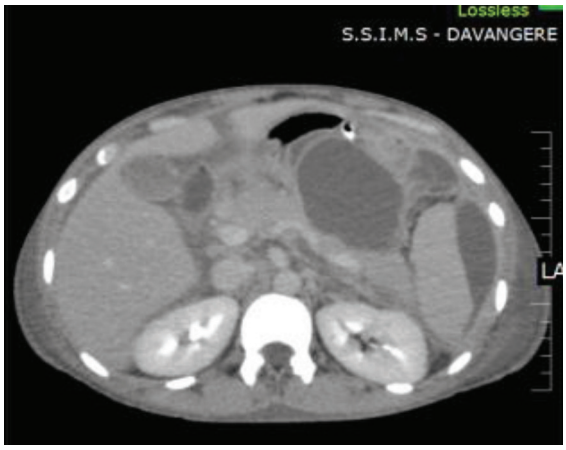


**Case-2:** Pseudocyst of the pancreas

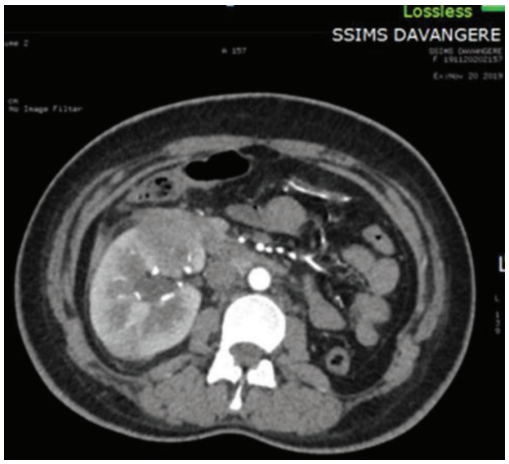


**Case-3:** Renal abscess

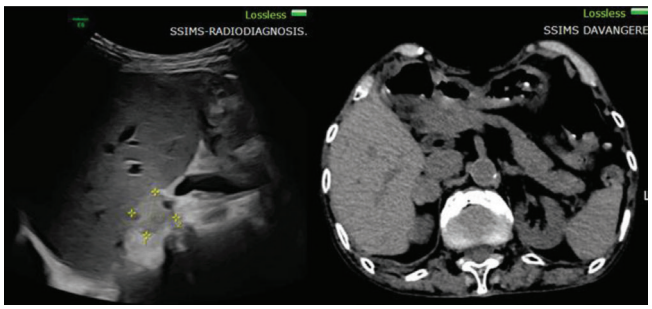


**Case-4:** Adrenal adenoma

**Appearance:** USG: Of the 28 cases, 19 cases (65%) were solid masses, 8 cases (27%) were cystic and 4 cases (9%) had both solid and cystic components. MDCT: 21 cases had solid appearing lesions of the 28cases. 6 cases had cystic lesions. 1 case had both solid and cystic components.

**Echotexture:** 67% of the masses were hypoechoic, followed by 26% of the masses were heterogenous. Only 6% of the masses were hyperechoic. Majority of the lesions were hypodense (75%), 2% of lesions were hyperdense and 22% of lesions were heterogenous.

**Enhancement pattern on MDCT:** Of the 28 cases, 18 lesions (51%) were showing homogenous pattern, 12 cases (32%) were non-enhancing and 6 lesions showed heterogenous enhancement.

**Vascularity of the masses by USG:** Mild vascularity was seen in 16 cases, moderate vascularity in 8 cases. 4 cases were avascular.

## DISCUSSION

The retro-peritoneum represents a complex potential space containing multiple vital structures limited anteriorly by the peritoneum, posteriorly by the posterior abdominal wall, superiorly by the 12$^{th}$ rib and vertebra, inferiorly by the base of the sacrum and iliac crest and laterally by the borders of the quadratus lumborum.[8,9] The retro-peritoneum is broadly divided into the anterior and posterior pararenal, perirenal and great vessel spaces.[10] The anterior pararenal space is bordered anteriorly by the posterior parietal peritoneum, posteriorly by the anterior renal fascia (Gerota's fascia) and laterally by the latero-conal fascia.[11] The anterior pararenal space is subdivided into the pancreatico-duodenal space, which contains the pancreas.[11]

MDCT remains the most widely available and most effective modality for detection and characterization of retroperitoneal mass[12]. A total of 36 patients were referred to our department with clinically diagnosed retroperitoneal mass or USG detected retroperitoneal masses.

In our study 11(30%) patients presented with abdominal pain, followed by loss of appetite (7 cases, 19%) and weight loss (5 cases 15%). 5cases (15%) of cases were discovered incidentally. They were valuated with ultrasound first and

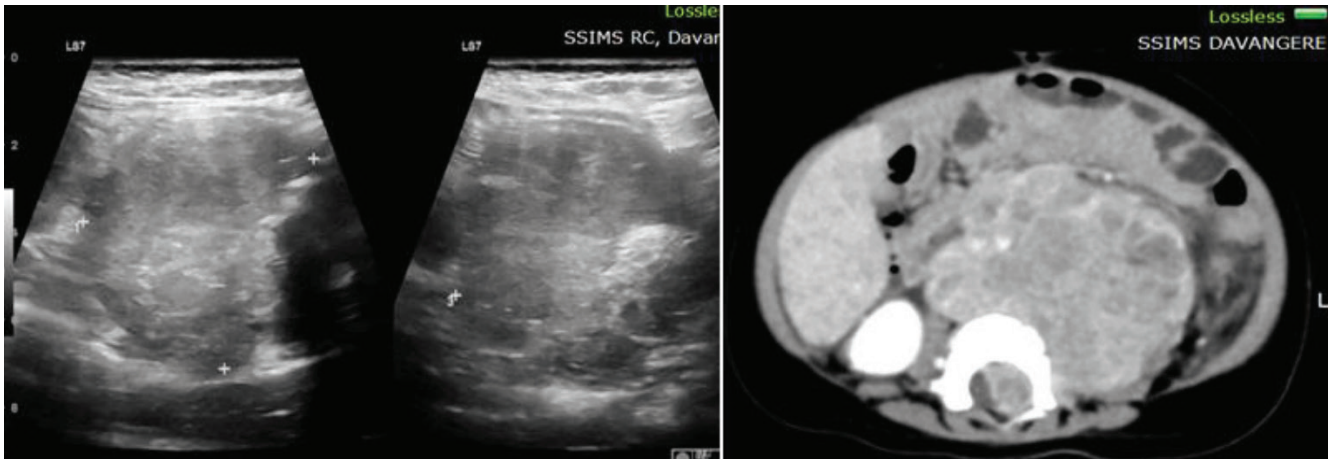


**Case-5:** Neuroblastoma

then MDCT was performed. Of the 36patients, 14 (38%) retroperitoneal masses were seen arising from the kidneys, followed by the adrenals (8 cases, 23%) and pancreas (5 cases, 14%). Other sites included the aorta and the psoas. Three Cases were primary retroperitoneal. One case was seen arising from the caecum. USG correctly identified the masses in 28 cases (sensitivity of 77%). MDCT was able to identify and characterize the masses in all the 36 cases. In our present study, the morphological characteristics of the retroperitoneal masses in USG included the size, appearance, echotexture in terms of echogenicity, vascularity on color Doppler and calcifications. MDCT characteristics included the size, density of the mass, enhancement pattern on post contrast and calcifications. Only 4 masses < 2cm could be identified by USG compared to 12 masses on MDCT.

On USG 38(67%) mass lesions were hypoechoic, 7 cases showed (26%) heterogeneous echotexture. Few masses were hyperechoic (2 cases, 6%). The vascular pattern of the masses on color Doppler was as follows: 59% (16 cases) of the cases were mildly vascular, moderate vascularity was noted in 28% (8 cases) of cases where as no vascularity was recorded in 12% (4 cases) of cases.

On MDCT, 27 lesions were hypodense (75%), 22% (8 cases) of the masses which were heterogenous. A small number of masses were hyperdense (1 case, 2%). Majority of the masses showed enhancement on intravenous contrast administration. 12 cases (32%) were non enhancing. 6 cases (17%) were heterogeneously enhancing. The masses showed enhancement in the arterial phase or in the venous phase after administration of contrast intravenously. MDCT identified calcifications in 7 cases compared to 4 cases by USG.

USG demonstrated the infiltration into surrounding structures in only 14% cases where as MDCT found infiltration in 44% of cases. Metastasis was noted in 7% of cases on ultrasound compared to 27% of cases on MDCT. Lymph nodal involvement was found in 22% on USG compared to 42% on MDCT.

**Renal Malignancy**

Out of 2 cases with renal mass, all were males with age >50 yrs of age. The margins of the lesions were irregular and ill defined. All the cases were heterogenous in echogenicity with few areas of necrosis. 1case showed few cysts within.1 case showed calcifications within. The ultrasound findings were further confirmed in MDCT.

**Pancreatic fluid collections**

Out of 3 cases (8%) of suspected acute pancreatitis that was referred for suspected, 2 cases were diagnosed with pseudocyst, one walled off necrosis. USG and MDCT could detect all the cases of pseudocysts and walled off necrosis that were diagnosed on CT.

**Pancreatic Head Mass**

2 patients (5.5%) with suspected pancreatic carcinoma were referred. Both USG and Contrast enhanced CT was done. USG showed the pancreatic mass as a hypoechoic lesion with associated IHBRD, dilated CBD and pancreatic duct in 1 case. These findings were further confirmed on MDCT. However, direct extension into the CBD and lymphadenopathy were better demonstrated on CT. In one case where the mass was <2cm US showed only indirect signs like CBD and MPD dilatation with IHBRD.

**Caecal mass**

1 case of caecal mass was encountered. USG identified caecal thickening with lymphadenopathy. However, MDCT was useful in evaluating and staging of the caecal mass.

**Psoas Abscess**

USG, CT and MRI were done in all the cases. All the cases were due to spondylodiscitis. USG demonstrated hypoechoic cystic area in the substance of the psoas muscles with internal echogenic debris in 1 out of 3 cases.

**Adrenal lesions**

Out of 8 cases, 4 cases were diagnosed as adrenal adenoma, 4 cases were myelolipomas. An adrenal metastasis cannot be distinguished clearly from benign lesions such as an adenoma, hematoma, pseudocyst or inflammatory mass on the basis of its morphology. The lesions were further confirmed on MDCT scan in all the cases. USG had missed 2 lesions which were demonstrated on CT. one case of adenoma and 1 cases of myelolipomas were missed on USG which were <2cm in size.

In a study done by Pant et al, USG correctly detected 46 out of the total 50 cases having an accuracy of 92% for the detection and evaluation of retroperitoneal lesions which is more than our previous study.[13]

In another study done by van Randen et al, sensitivity of CT was significantly higher than that of ultrasound. The reported sensitivities for ultrasound in experienced high as 90% as compared to CT which was significantly higher than that of ultrasound, i.e. 94% which is more than our study.[14]

In another study done by Manoj et al, recommends USG as the primary tool for evaluating retroperitoneal lesions and CT for confirmation and for evaluating the complete extent of the lesion. In our rural India setup, these modalities have to be tailored to the clinical need and the socioeconomic status of the patient[15].

CT is useful than USG in diagnosis and assessment of size and extent of retroperitoneal tumors, as well as assess the involvement of organs and vasculature with resection in mind[15].

In a study done by Chinwan et al, since most of the retroperitoneal masses have heteroechoic/ mixed pattern, they cannot be characterised by ultrasound alone and hence need further evaluation with MDCT.[16]

## CONCLUSION

Imaging plays an important role in the treatment of patients with acute abdominal pain and evaluation of retroperitoneal masses[17]. USG and MDCT have 77% and 100% sensitivity respectively in evaluation of masses when compared with surgical findings. USG has an accuracy of 78% in determining the lesions. It is less sensitive for the detection and characterization of retroperitoneal masses smaller than 2cm compared to MDCT.[18] We recommend USG as the primary tool in evaluation of retroperitoneal lesions. MDCT has to be done for confirmation and for evaluating the complete extent of the lesion and guiding the surgeon for further surgical planning.[19]


ISSN (Online): 2565-4810; (Print): 2565-4802 | ICV 2019: 98.48 |

## REFERENCES


1. Thornton FJ, Kandiah SS, Monkhouse WS. Helical CT evaluation of the perirenal space and its boundaries: a cadaveric study. Radiology 2001; 218(1):659–663.
2. Gore RM, Balfe DM, Aizenstein RI, Silverman PM. The great escape: interfascial decompression planes of the retroperitoneum. Am J Roentgenol 2000; 175(4):363–370.
3. Pant H, Shukla S, Ahmad R. Role of ultrasound in evaluation of retroperitoneal lesions. J Evol Med Dent Sci. 2016;5(53):3563–8.
4. Coffin A, Boulay-Coletta I, Sebbag-Sfez D, Zins M. Radioanatomy of the retroperitoneal space. DiagnInterv Imaging. 2015;96(2):171–86.
5. D H, B S, Swamy S, K U V K. role of ultrasonography and ct in the evaluation of abdominal masses. J Evid Based Med Healthc. 2015;2(42):7166–84.
6. Kawashima A, Sandler CM, Corl FM, West OC, Tamm EP, Fishman EK, et al. Imaging of Renal Trauma: A Comprehensive Review. Radiographics. 2001;21(3):557–74.
7. Shuman WP, Ralls PW, Balfe DM, et al. Imaging evaluation of patients with acute abdominal pain and fever. American College of Radiology. ACR Appropriateness Criteria. Radiology. 2000;215(Suppl):209–212.
8. Nishino M, Hayakawa K, Minami M, Yamamoto A, Ueda H, Takasu K. Primary retroperitoneal neoplasms: CT and MR imaging findings with anatomic and pathologic diagnostic clues. Radiographics 2003; 23(4):45–57.
9. Hayasaka K, Yamada T, Saitoh Y, Yoshikawa D, Aburano T, Hashimoto H, et al. CT evaluation of primary benign retroperitoneal tumor. Radiat Med. 1994;12(3):115-20.
10. Grainger RG, Allison DJ, Adam A, Dixon AK. Diagnostic radiology. 4th ed. London: Churchill Livingstone; 2001.
11. Van Randen A, Laméris W, van Es HW, et al. A comparison of the accuracy of ultrasound and computed tomography in common diagnoses causing acute abdominal pain. Eur Radiol. 2011;21(7):1535-1545.
12. Neville A, Herts BR. CT characteristics of primary retroperitoneal neoplasms. Crit Rev ComputTomogr 2004; 45(6):247–270.
13. Pant H, Shukla S, Ahmad r. Role of ultrasound in evaluation of retroperitoneal lesions. J Evol Med Dent Sci. 2016;5(53):3563-8.
14. Stoker J, Randen A, Laméris W, Boermeester MA. Imaging patients with acute abdominal pain. Radiology. 2009; 253(4):31–46.
15. Manoj MC, Prabhu CS, Lokesh kumar T et al. Current status of ultrasonography in the evaluation of the retroperitoneal masses : a review. Int J Sci Res. 2020; 2277-8179-9.
16. Diksha Chinwan, Poonam Vohra.F Int J Res Med Sci 2018; 6(12): 3949-3953.
17. Puylaert JB. Ultrasonography of the acute abdomen: gastrointestinal conditions. Radiol Clin North Am. 2003; 41(4):1227–1242.
18. Shaaban AM, Rezvani M, Tubay M, Elsayes KM, Woodward PJ, Menias CO. Fat-containing Retroperitoneal Lesions: Imaging Characteristics, Localization, and Differential Diagnosis. Radio Graphics. 2016;36(3):710-34.
19. Hatimota P, Vashist S, Aggarwal K, Kapoor A, Gupta NP. Spectrum of US and CT findings in renal neoplasms with pathologic correlation. Indian J Radiol Imaging. 2005;15(1):117.


**Source of Support:** Nil; **Conflict of Interest:** None

**Submitted:** 20-06-2020; **Accepted:** 20-11-2020; **Published online**: 23-03-2021