

Frequency and Distribution Pattern of Minor Salivary Gland Tumors: A Clinicopathological Retrospective Study

P. Sreenivasa¹, Raghuveer V Bhosle²

¹Associate Professor, ²Assistant Professor, Department of General Surgery, MNR Hospital Sangareddy, Telangana, India

Corresponding author: Raghuveer V Bhosle, Assistant Professor, Department of General Surgery, MNR Hospital Sangareddy, Telangana

How to cite this article: P. Sreenivasa, Raghuveer V Bhosle. Frequency and distribution pattern of minor salivary gland tumors: a clinicopathological retrospective study. *International Journal of Contemporary Medicine Surgery and Radiology*. 2018;3(1):84-86.

A B S T R A C T

Introduction: Minor salivary gland tumors account less than 25% of overall salivary neoplasms. The presence of minor salivary gland may induce particular signs and symptoms depend on the location. SGT demonstrates variations in their clinic-pathological profile related to generations, racial and geographic differences. The study was undertaken to evaluate the frequency, location and histopathological type of minor salivary gland tumors in Indian population of telangana region.

Material and Methods: Total numbers of 127 minor salivary gland tumor cases are identified from medical records of various hospitals in Hyderabad for the period of 5 years. The data regarding the frequency, histopathological type, location of minor salivary gland tumors was noted down and tabulated using the standard statistical package for social sciences (SPSS).

Results: Out of 127 cases, 60.6% were males and 39% were females. Benign tumors are identified in higher cases (58.2%), malignant tumors are found in 41.7% of the cases. Palate is cited higher number of benign and malignant tumors.

Conclusion: The frequency of minor salivary gland tumors are more affected in men. Clinical data showed in the study are similar with majority of studies in several other regions of India.

Key words: Salivary Gland Neoplasm, Tumors, Benign, Malignant, Histopathological

INTRODUCTION

Salivary gland tumors (SGT) usually located as a swelling or lump in the affected gland which may or may not have been present for a long time. The swelling may be accompanied by symptoms of duct blockage¹. The early stages of SGT are not possible to distinguish a benign tumor from a malignant one². The neoplasm of salivary gland is a distinct group of lesions with varying morphology, which shows challenges in their diagnosis and treatment. SGT presents distinct characteristics, especially regarding its frequency, distribution, and clinical aspects. Worldwide studies reported that geographic location and ethnic factors may affect clinicopathological profile of salivary tumors^{3,4}. The etiology of salivary tumors has not been recognized perfectly, certainly; ionizing radiation, vitamin A deficiency, sunlight, smoking and chemotherapy have been pointed out in the previous studies^{4,5}.

The majority of salivary gland tumors are benign (65-70%), 75% of the parotid gland tumors are benign, and around 50% of the tumors found in the submandibular glands are benign⁶. Most of the sublingual gland tumors are likely to be malignant and its presence is very rare. Literatures that evaluate the epidemiology of minor salivary gland neoplasm represent less than 25% of intraoral salivary neoplasm. Most of the minor salivary gland tumors are often malignant, in particular when compared to neoplasms of major salivary glands^{6,7}. SGT demonstrates variations in their clinic-pathological profile

related to generations, racial and geographic differences. Few studies observed SGT differences between race and geographic location. Considering the limited studies, the present study was investigated on large group of patients in Indian population.

Salivary gland tumors are relatively uncommon, presents 3-6% of all head and neck neoplasms in various studies⁸. Still, these tumors are significant in the pathology of head and neck because of hard diagnosis, management and unpredictable clinical course of disease. The accurate diagnosis of salivary gland tumors is imperative for the prognosis and management of disease^{9,10}. The patients age, gender, site of lump and relative incidences are important for the diagnosis of salivary tumors. Literature shows, most of the studies include major and minor salivary gland tumors together. The current demographic study was undertaken to evaluate the minor salivary gland tumors in Indian population of telangana region for 5 years.

MATERIAL AND METHODS

The present retrospective study was carried out in department of surgery, MNR Medical College and Hospital, Sangareddy, and Telangana. The clinical data (age, gender, site of lesion and histopathological type) of patients were collected from the medical records of various hospitals in located in and around Hyderabad, over a period of 5 years. Total numbers of 127 minor salivary gland tumor cases were evaluated during the study period. Salivary gland tumors histopathologically

Histological type	Palate	Oral Mucosa	Gingiva	Lip	Floor of the mouth	Retromolar area	Total
Benign tumors:							
Pleomorphic adenoma	34	7	-	-	4	-	45
Myoepithelioma	8	3	-	2	3	-	16
Basal cell adenoma	7	-	1	-	1	4	13
Malignant tumors:							
Mucoepidermoid carcinoma	12	-	-	-	-	4	16
Adenocarcinoma	7	1	-	-	1	-	9
Acinic cell carcinoma	3	3	-	2	-	3	11
Polymorphous low grade adenocarcinoma	5	-	2	-	1	1	9
Basal cell adenocarcinoma	-	1	-	-	3	1	5
Adenoid cyst carcinoma	-	-	1	-	-	2	3

Table-1: Frequency and Location of minor salivary gland tumors based on histological type.

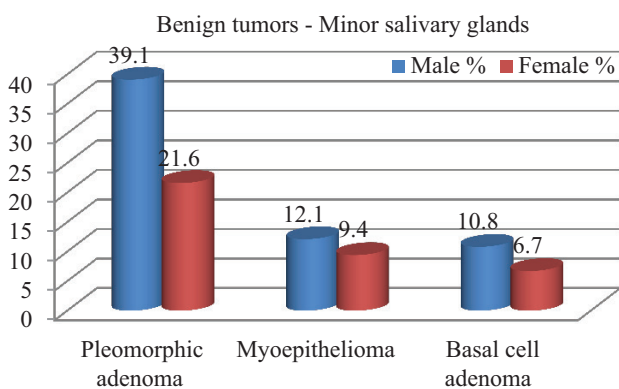


Figure-1: Frequency of benign minor salivary gland tumors according to histology type and sex

identified in the minor salivary glands are included, whereas recurrent, metastatic and major salivary gland tumors were excluded from the study. The samples with doubtful diagnosis are also excluded from the study. The study was scrutinized and approved by institutional ethical committee.

STATISTICAL ANALYSIS

The data were entered in excel sheet and tabulated using the standard statistical package for social sciences (SPSS).

RESULTS

Among several records, 127 cases were diagnosed as minor SGTs. Out of 127, 77 (60.6%) were males and 50 (39%) were females. The mean age was 39.2 ± 15.3 years with range from 7-79 years in both sexes. Out of all minor salivary gland neoplasms, 74 (58.2%) were benign and 53 (41.7%) were malignant (Figure 1). Based on histological type, the frequency, location of minor salivary gland tumors are detailed in table 1. Pleomorphic adenoma (PA) was the most common tumor observed in 60.8% of cases in benign minor SGTs, followed by Myoepithelioma in 21.6% and Basal cell adenoma in 17.5% (Figure 2). Most of the benign tumors are located in palate region. Out of 53 malignant tumor cases, Mucoepidermoid carcinoma was the most common malignant salivary tumors found in 30.1% of the cases. The higher number of mucoepidermoid carcinomas are identified around palate region (table-1).

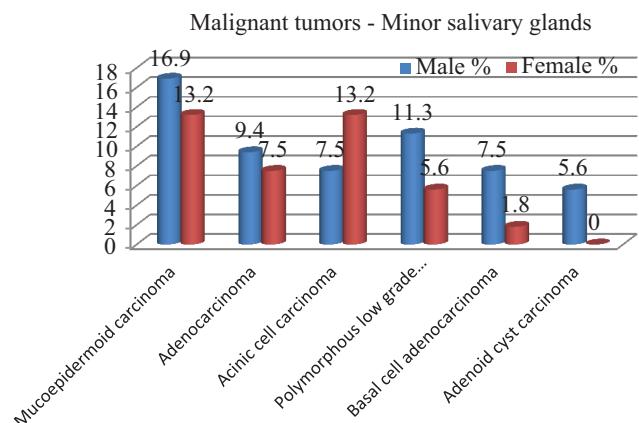


Figure-2: Frequency of malignant minor salivary gland tumors according to histology type and sex

DISCUSSION

Minor salivary gland tumors may be associated with symptoms which not have been present for long time¹¹. Irrespective of their location, the major salivary gland tumors shows the symptoms like facial pain, facial palsy, paraesthesia, and other red flag symptoms. The symptoms of minor salivary neoplasm may vary depends on the location, size, related nerve involvement and blockage of the duct. The red flag symptoms may indicates malignancy and warrant for further investigation are ulceration, fixation of the lump to the overlying skin and induration of the mucosa. Most common sign observed in minor salivary gland tumor is lump or swelling. The other signs and symptoms observed in minor salivary gland tumors are difficulty in speaking, ulceration and ill-fitting dentures. Although, we found the presence of pain and ulceration more commonly for malignant tumors, other signs and symptoms did not significantly differ between benign and malignant neoplasm of minor salivary glands.

It is important to diagnose the type of minor salivary gland tumor; there were many diagnostics methods available like history and physical examination of the patient, endoscopy, biopsy, Fine needle aspiration (FNA) biopsy, radiographs, ultrasound and MRI¹². Radiographs are useful to rule out the mandibular involvement and any other secondary tumors. Ultrasound can be used initially to asses a tumour involvement in particular salivary gland, but the exact location and extent

can be identified with advanced radiographic techniques like MRI. The SGTs are categorized into many different terms and classification systems due to the diverse nature of tumors. But, the most widely accepted classification system proposed by world Health Organization (WHO) in 2004^{11,12}.

The data of the present study showed that minor salivary gland tumors were most frequent in men. Minor salivary gland tumors are heterogeneous and rare group lesions. Benign tumors (58.2%) are observed in higher cases in the current study and this data is in agreement with reports of Al-Khateeb TH et al¹³, Subhashraj K¹⁴, Pires FR et al¹⁵, Buchner A et al¹⁶. we have found in literature that some authors disagree with the observations of present study like Wang D et al¹⁷, Copelli C et al¹⁸, Venkata V¹⁹. Out of 74 benign minor SGTs, Pleomorphic adenoma (60.8%) reported in most of the cases followed by Myoepithelioma (21.6%) and Basal cell adenoma (17.5%). These results are in concurrent with Pires F R¹⁵, Wang D¹⁷.

In malignant tumors of minor salivary gland, the Mucoepidermoid carcinomas were the most common lesion found in the current data, followed by adenocarcinoma, acinic cell carcinoma and polymorphous low-grade adenocarcinoma. Our data is in contrast with the results reported by the Pires FR¹⁵, De Oliveira FA et al²⁰, Dhanuthai et al²¹. Kruse et al²², reported that adenoid cystic carcinoma was the most prevalent lesion, in disagreement with present data.

CONCLUSION

The demographic data about clinical and histopathological characteristics of minor salivary gland neoplasm are similar with majority of research studies reported in several other regions of India. We conclude that the incidence of minor salivary gland tumors are more affected in men, pleomorphic adenoma of benign variety, Mucoepidermoid carcinomas of malignant variety was the most common minor salivary gland tumors. Moreover, future studies are inviting with large group of population and major salivary gland tumors need to be evaluated statistically with demographic incidences and histological characteristics.

REFERENCES

1. Speight PM, Barrett AW. Salivary gland tumours. *Oral Dis.* 2002;8(2):229-40.
2. Ansari MH. Salivary gland tumors in an Iranian population: A retrospective study of 130 cases. *J Oral Maxillofac Surg.* 2007;65(4):2187-94.
3. Kayembe MK, Kalengayi MM. Salivary gland tumours in Congo (Zaire). *Odontostomatol Trop* 2002; 25(1): 19-22.
4. Shishegar M, Ashraf MJ, Azarpira N, et al. Salivary gland tumors in maxillofacial region: a retrospective study of 130 cases in a southern Iranian population. *Patholog Res Int* 2011; 50(3): 1-5.
5. Licitra L, Grandi C, Prott FJ, et al. Major and minor salivary glands tumours. *Crit Rev OncolHematol* 2003; 45(6): 215-217.
6. Hashemi P, Zarei MR, Chamani G, et al. Malignant salivary glands tumors in Kerman province: a retrospective study. *Dent Re J* 2007; 4(3): 4-10.
7. Odukoya O. Pleomorphic adenoma of salivary glands in Lagos, Nigeria. *Afr J Med Sci.* 1990;19(6):195-9.
8. Ansari M. Salivary gland tumors in an Iranian population: a retrospective study of 130 cases. *J Oral Maxillofac Surg.* 2007;65(5): 2187-94.
9. Waldron CA, el-Mofty SK, Gnepp DR. Tumors of the intraoral minor salivary glands: A demographic and histologic study of 426 cases. *Oral Surg Oral Med Oral Pathol.* 1988;66(4):323-33.
10. Eveson JW, Cawson RA. Tumours of the minor (oropharyngeal) salivary glands: A demographic study of 336 cases. *J Oral Pathol.* 1985;14(2):500-9.
11. Otoh EC, Johnson NW, Olosoji H, et al. Salivary gland neoplasms in Maiduguri, north-eastern Nigeria. *Oral Dis* 2005; 11(3): 386-91.
12. Ramesh M, Krishnan R, Paul G. Intraoral minor salivary gland tumours: a retrospective study from a dental and maxillofacial surgery centre in Salem, Tamil Nadu. *J Maxillofac Oral Surg.* 2014;13(2):104-8.
13. Al-Khateeb TH, Ababneh KT. Salivary tumors in north Jordanians: a descriptive study. *Oral Surg Oral Med Oral Pathol Oral RadiolEndod.* 2007;103(5):e53-9.
14. Subhashraj K. Salivary gland tumors: a single institution experience in India. *Br J Oral Maxillofac Surg.* 2008;46(8):635-8.
15. Pires FR, Pringle GA, de Almeida OP, Chen SY. Intra-oral minor salivary gland tumors: a clinicopathological study of 546 cases. *Oral Oncol.* 2007; 43(5):463-70.
16. Buchner A, Merrell PW, Carpenter WM. Relative frequency of intra-oral minor salivary gland tumors: a study of 380 cases from northern California and comparison to reports from other parts of the world. *J Oral Pathol Med.* 2007;36(4):207-14.
17. Wang D, Li Y, He H, Liu L, Wu L, He Z. Intraoral minor salivary gland tumors in a Chinese population: a retrospective study on 737 cases. *Oral Surg Oral Med Oral Pathol Oral RadiolEndod.* 2007;104(1):94-100.
18. Copelli C, Bianchi B, Ferrari S, Ferri A, Sesenna E. Malignant tumors of intraoral minor salivary glands. *Oral Oncol.* 2008;44(7):658-63.
19. Venkata V, Irulandy P. The frequency and distribution pattern of minor salivary gland tumors in a government dental teaching hospital, Chennai, India. *Oral Surg Oral Med Oral Pathol Oral RadiolEndod.* 2011;111(1):e32-9.
20. De Oliveira FA, Duarte EC, Taveira CT, Máximo AA, de Aquino EC, Alencar Rde C, et al. Salivary gland tumor: a review of 599 cases in a Brazilian population. *Head Neck Pathol.* 2009;3(4):271-5. Review.
21. Dhanuthai K, Boonadulyarat M, Jaengjongdee T, Jiruedee K. A clinico-pathologic study of 311 intra-oral salivary gland tumors in Thais. *J Oral Pathol Med.* 2009; 38(6):495-500.
22. Kruse AL, Grätz KW, Obwegeser JA, Lübbers HT. Malignant minor salivary gland tumors: a retrospective study of 27 cases. *Oral Maxillofac Surg.* 2010; 14(4):203-9.

Source of Support: Nil; **Conflict of Interest:** None

Submitted: 20-01-2018; **Published online:** 28-02-2018