ORIGINAL RESEARCH ARTICLE

Role of Magnetic Resonance Imaging in Identifying the Different Imaging Patterns of Viral Encephalitis

Kavita Umesh Vaishnav[1], Janki Jaradi[2], Rahul Solanki[3], Amisha Patel[4], Balasubramanian Vignesh[5]

[1]Associate Professor, [2]Assistant Professor, [3]3rd Year Resident, [4]2nd Year Resident, [5]3rd Year Resident, Department of Radiodiagnosis, L.G. Hospital, AMC MET Medical college, India

Corresponding author: Dr. Janki Jaradi, M.D. Assistant Professor, Department of Radiology, 6/12, Umasut Flats, Opposite Godavari Nagar Part 1, Vasna, Ahmedabad -380007, India

DOI: http://dx.doi.org/10.21276/ijcmsr.2018.3.4.24

How to cite this article: Kavita Umesh Vaishnav, Janki Jaradi, Rahul Solanki, Amisha Patel, Balasubramanian Vignesh. Role of magnetic resonance imaging in identifying the different imaging patterns of viral encephalitis. International Journal of Contemporary Medicine Surgery and Radiology. 2018;3(4):D104-D108.

ABSTRACT

Introduction: Encephalitis is critical life threatening acute infection of brain parenchyma. There has been a significant decrease in morbidity and mortality in patients with intracranial infection with the advent of Magnetic Resonance Imaging (MRI) which helps in treatment plan and follow up for complications. The purpose of this study was to describe the role of MRI in the evaluation of parenchymal changes in patients clinically suspected for brain infection.

Material and methods: All the patients clinically suspected with brain infection were referred for MRI study of brain with or without contrast to the department of Radio diagnosis, LG hospital during the period of March 2016- June 2018 were evaluated to detect changes of encephalitis. The data was analyzed and Epi info version 7 was used for statistical calculations.

Result: Total 29 patients were taken in our study. Patients from all age group were included in the study, in which 10 were females and 19 were male. Rasmussen encephalitis in three and acute disseminated encephalomyelitis (ADEM) was diagnosed in four patients. Chickungunya, dengue and epstein Barr virus (EBV) was diagnosed in one patient each. Four patients had Japanese encephalitis and two patients had meningo encephalitis. Six patients had hemorrhagic areas with in the lesions. The findings of MRI were compared with the clinical presentation and follow up was obtained in some patients after treatment.

Conclusion: MRI was found to be superior in visualization of the brain parenchymal involvement and its associated findings. MRI is helpful to reach the diagnosis of etiological factor, but laboratory investigation is helpful for confirmatory diagnosis.

Key words: Brain, Encephalitis, Viruses, MRI (Magnetic Resonance Imaging)

INTRODUCTION

Encephalitis is defined as acute, diffuse inflammation of the brain tissue with parenchymal infiltration of various inflammatory cells commonly by virus. The brain damage is due to either intracellular viral load or host inflammatory response. Infections of the nervous system and adjacent structures are often critical life-threatening conditions. The prognosis of it mainly depends on rapid identification of the site of inflammation and probable pathogen to provide proper treatment as early as possible. Still analysis of cerebrospinal fluid (CSF), biopsy, and laboratory investigations remain the gold standard to identify the etiological factor for encephalitis. But, some typical MRI imaging features of lesion allows a rapid diagnosis and help in subsequent therapeutic management. Notably, MRI has a pivotal role not only in the early diagnosis but also in monitoring therapeutic response and complication.

The purpose of this study was to describe the role of MRI in the evaluation of encephalitis in patients clinically suspected of brain infection. Clinical indications, imaging techniques, and illustrations of relevant conditions are presented.

- To help in the diagnosis of the encephalitis.
- To provide any additional information.

In combination with IgM against the virus in cerebral spinal fluid and clinical presentation helps to reach the correct diagnosis

MATERIAL AND METHODS

All the patients suspected for encephalitis were referred for MRI brain with or without contrast studies done in the department of Radio diagnosis, LG hospital during the period of March 2016 - June 2018, were evaluated to detect changes of encephalitis. This study has been performed using 1.5T SIEMENS MRI scan machine using head coil. MR imaging of the brain was performed using a tailor made protocol. Basic imaging protocol consisted of fast spin echoT2 Weighted Imaging (WI) in axial and sagittal planes and; Diffusion Weighted imaging (DWI), T1WI in axial plane and Fluid attenuation inversion recovery (FLAIR) images in coronal plane. Gradient echo images (GRE) were performed in axial plane. Contrast studies were performed when requested by clinicians. While performing MRI scan,

ISSN (Online): 2565-4810; (Print): 2565-4802 | ICV 2017: 69.52 |

sedatives were used under the supervision of the anesthetist according to the requirement which was decided by the anesthetics in selected patients. Written and informed oral consent of the patients and their relatives were obtained prior to the study.

Type of study – Single centered retrospective study

Inclusion criteria –

- All patients suspected for encephalitis referred for MRI included in the study

Exclusion criteria

- Patients with absolute contraindication for MRI

RESULT

Total of 29 cases which were referred to the department of radio diagnosis for the MRI study of brain suspected with viral encephalitis were taken up for our study. Out of these, ten cases were females and nineteen were males. Among 18 adult patients, two patients expired. Three patients expired out of 11 pediatric patients. Follow up was not available in nine patients out of the remaining 24. Follow up of 16 patients was obtained from the treating consultants. All the remaining patients showed good prognosis following treatment with few showing minimal neurological deficit.

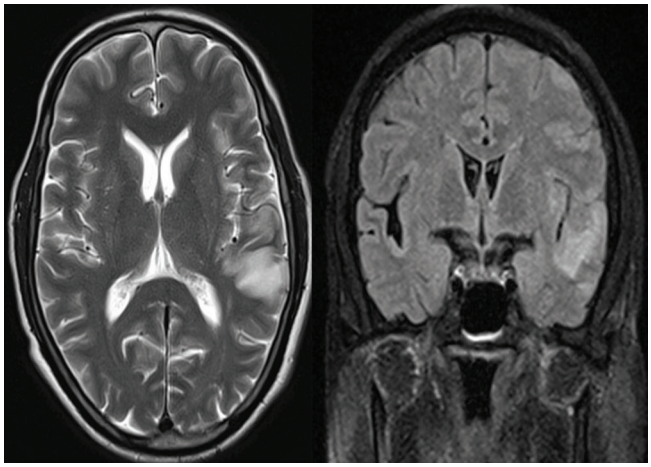

Figure-1: Case of herpes encephalitis showing illdefined hyperintese areas in left temporal region on T2 W axial image and Flair coronal image.

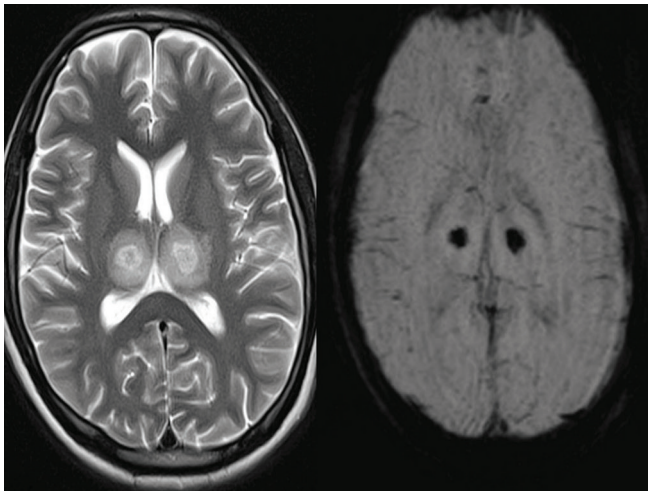

Figure-2: Case of Japanese encephalitis showing symmetrical hyperintensity in bilateral thalamus on T2 axial images and hypointese foci in both thalamus on axial SWI images, hypointese foci in right thalamus suggestive of haemorrhagic foci.

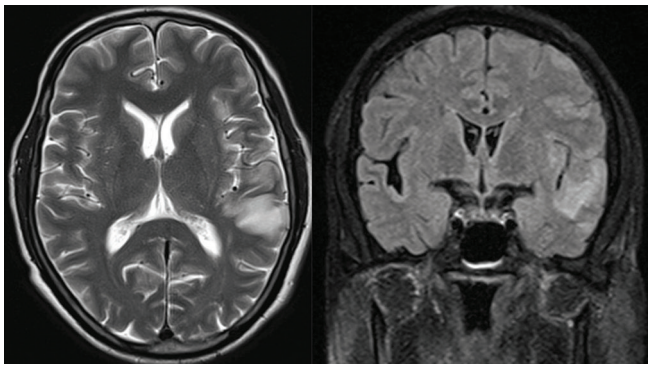

Figure-3: Case of ADEM showing illdefined hyperintese areas in bilateral parietal region on T2 W axial image and Flair coronal image.

MRI diagnosis	Frequency	Percentage
Acute disseminated encephalomyelitis	4	13.79%
Chickungunya encephalitis	1	3.45%
Epstein barr virus encephalitis	1	3.45%
Viral encephalitis	12	41.38%
Herpes encephalitis	2	6.90%
Japanese encephalitis	4	13.79%
Meningoencephalitis	2	6.9%
Rasmussen encephalitis	3	10.34%
Total	29	100.00%

Table-1: Based on MRI diagnosis of encephalitis

The age group of the patients ranged from 2 months to 82 years with a median age of 27 years. The majority of patients presented with complaint of fever, headache, neck rigidity, convulsion, coma, vomiting and confusion. Most of these clinical features were seen in combination with each another. In all the patients, CSF examination was done to differentiate between viral and bacterial encephalitis. Diagnosis was done based on correlation between the presenting clinical features, CSF examination and MRI findings.

In our study, 10 patients were female and 19 patients were male. All the patients had complaints of fever and headache. 75% of the patients presented with complaint of neck rigidity. 58% of patients had convulsions and confusion. 52% percent of patients presented with vomiting. 45% of the patients had coma.

In our study, 18 (66%) patients showed involvement in both cerebral hemispheres. 4 (14%) patients show involvement of left hemisphere and 7 (26%) patients showed involvement of right hemisphere.

Out of 29 patients, 8 patients had contrast study done in which 4 patients showed post contrast enhancement.

In T2WI and FLAIR images, 24 patients showed hyper intensities. 22 patients showed diffusion restriction on DWI. In pediatric patients diffusion weighted imaging showed diffusion restriction in all cases. Hence, diffusion weighted

ISSN (Online): 2565-4810; (Print): 2565-4802 | ICV 2017: 69.52 |

imaging is more sensitive in the detection of encephalitis in pediatric patients. T2 W and FLAIR images may be inconsistent in these cases with few appearing normal and few showing hyper intensities.

Hypo intensities/blooming was noted in SWI in 6 patients.

In 58% of the cases parietal lobe was involved. In 55% and 52% of the patient temporal and frontal lobes were involved respectively. In 34% of the patient's basal ganglia and capsular region was involved. In 27% and 20% of the cases occipital and thalamic regions were involved. Cerebellar involvement was noted in 13% of the cases. Midbrain and corpus callosum was noted in 10% and 6% of the cases.

DISCUSSION

Encephalitis is defined as acute, diffuse inflammation of the brain tissue. Unfortunately, in some people, encephalitis may coexist with meningitis, which is inflammation of layers of brain tissue leading to a more complex diagnosis and treatment plan. In addition, both conditions share many of the symptoms and presentation so they may be difficult to distinguish. Encephalitis presents with a variety of symptoms like confusion, fever, headache, stiff neck and back, nausea, vomiting, drowsiness and coma.

Neurologic manifestations arise at the acute viremic stage of infection with direct invasion of the central nervous system by the virus which probably accounts for the encephalitic form of the disease.[1] In addition, the presence of IgM against virus in the CSF supports the theory of neuroinvasion by virus.

The symptoms of encephalitis are often non-specific, with a variety of non specific symptoms, making it clinically difficult at an early stage to distinguish from other neurological syndromes. Sometimes both infectious and immune-mediated pathogeneses must be considered. Approximately one-third of cases is immune-mediated, most frequently acute disseminated encephalomyelitis (ADEM).

Encephalitis has many causes, but for a majority of the patients it remains unknown. We aimed to establish the cause and try to identify the different imaging patterns between the various causes of encephalitis at our hospital. There are many causes of encephalitis like viruses, bacteria, parasites, chemicals, and even autoimmune reactions. Various viruses like Herpes simplex virus (HSV-1, HSV-2), varicella zoster virus (VZV), cytomegalovirus (CMV), Epstein-Barr virus (EBV), human herpes virus 6 (HHV6) and other adenoviruses. Rabies and arboviruses like Japanese B encephalitis and other viruses have also been implicated as the causative agents of encephalitis but are not commonly found in our setup.

Early diagnosis and early administration of treatment are crucial for decreasing mortality and morbidity from encephalitis.[4] However role of imaging methods in the management of encephalitis remains limited in confirmation of diagnosis and follow-up of complications.[5] Imaging helps in identifying the extent of the lesion, surrounding pattern of edema which also contribute to determine the underlying type of infection and possible causative agent; however, correlation with clinical findings and laboratory investigations are necessary for characterization of infectious agents.[5]

Herpes Simplex Virus (HSV) remains the most common cause of acute encephalitis worldwide. Both HHV-6 and HSV are members of the herpes family and have several similarities in presentation. They are neurotropic viruses and occasionally invade the CNS, causing encephalitis, meningitis, and myelitis.[6,7] They can establish latency in the host after primary infection and should receive attention as pathogens, especially in immune compromised and debilitated patients.[6,8]

MRI shows typical bilateral involvement of medial temporal and orbital surface of frontal lobes.[9] Which appears hypo intense on T1W, hyper intense on T2W and shows diffusion restriction. (figure 1)

Even in recent era detection of specific virus DNA in the CSF by PCR remains the mainstay for the diagnosis of encephalitis,[10] although results of this laboratory test may be false negative or may arrive belatedly.

Thus, results of imaging studies play a crucial role in deciding the treatment regimen and whether antiviral treatment has to be started in patients with suspected HSV encephalitis. In infants and neonates, DWI appears to be more sensitive than T2WI or FLAIR imaging in early detection of the cytotoxic cortical edema.[11]

Since EBV has predilection for the deep nuclei, showed low signal intensity on T1 W images and high intensity on T2 W images in both basal ganglia predominantly in the putamen; while the brain computed tomography scan showed only mild edema.[12] MRI can show characteristic multiple foci of T2-weighted or FLAIR hyper intensity in the cerebral cortex, brain stem, bilateral thalami, and basal ganglia. Rarely extensive white matter lesions have been reported in patients with chronic EBV infection and clinical relapse of neurologic problems.[13] These MRI changes were similar to Ono et al.[14]

Japanese encephalitis is a serious infection and has a significant mortality and morbidity. The most characteristic finding is hyper intense lesions in bilateral thalami on T2 W and FLAIR images on MRI.[15] On T1W images, the lesions appears hypo intense while lesions may show hemorrhagic transformation which appears as T1 hyper intensity. Hemorrhagic areas appear as "blooming" on gradient echo (GRE) MR images.[16] However, diffusion weighted MR sequences have the advantage over T2W and Flair images of detecting more number of lesions, their detection earlier than any other means, as well as identifying the stage of infection. MRI reveals restricted diffusion and low ADC values on diffusion imaging in case of acute JE due to ischemia and cytotoxic edema due to perivascular cuffing. In the sub acute stage of the disease, the degree of diffusion restriction decreases in DW image and ADC starts rising while in chronic stage there will be necrosis and demyelination results in hypo intensity on DW1 and high ADC values.[17]

MRI imaging shows bilateral thalamic lesions with or without hemorrhage. Lesions are also noted in the sustantia nigra, brain stem, cerebellum, cerebral cortex, and white matter.[18,19] (figure 2)

Chickungunya encephalitis shows a clinical presentation similar to that of dengue encephalitis. However, in case of Chickungunya encephalitis there is hyper intense white

ISSN (Online): 2565-4810; (Print): 2565-4802 | ICV 2017: 69.52 |

matter lesions on T2-weighted images with restricted diffusion.[20]

Chickungunya encephalitis is suspected in patient showing serum positivity for Chickungunya coupled with symptoms of encephalitis.

MRI showed sub cortical white matter, multiple tiny hyper intense areas were seen in T2-weighted and fluid-attenuated inversion recovery images. Such findings were also reported in patients with Chickungunya encephalitis in India.[21,22]

In patients with clinical presentation similar to that of dengue fever and with symptoms related to nervous system, the possibility of encephalitis must be taken into consideration. MRI findings in dengue encephalitis are mostly nonspecific, and these findings can be seen in Japanese and herpes encephalitis. In difficult cases, serological examination is helpful in differentiating it from other viral encephalitis. Dengue encephalitis shows diffuse cerebral edema, bilateral symmetrical hyper intense areas in thalami, pons, and medulla on T2 W and FLAIR images with heterogeneous or peripheral enhancement on post contrast images, with few of these areas showed restriction on diffusion and sometimes petechial hemorrhages. Our findings were comparable to cases described by Bhoi *et al*.,[23] Souren *et al*.,[24] and Jayaseelan *et al*.,[25] Restriction on diffusion similar to our case series was also described by Bhoi *et al*. Pal *et al*.[24]

Acute disseminated encephalomyelitis (ADEM) is an immune-mediated inflammatory demyelinating disease of the brain and spinal cord. Usually it is a monophasic illness, which may occur after viral infection, after vaccination, in association with rheumatic fever, or without any recognized antecedent disease. However, the disease is self limited, with complete or marked clinical recovery. Permanent neurologic deficit is seen in about 10% to 30% of patients, and mortality is 10%. MRI shows variable sized, asymmetrical, patchy areas of hyper intensity is seen involving the deep and sub cortical white matter, cerebellum and it may involves brain stem on T2 W images. Sometimes it may involve spinal cord.[26,27] In case of severe ADEM there may be hemorrhage within the lesions. DW images show peripheral restriction of the lesions. Post contrast T1W images may shows nodular, patchy and gyriform enhancement of the lesions. Clinical correlation is always essential to narrow down the differential diagnosis for this entity (figure 3).

Rasmussen encephalitis (RE) is a rare disease of unknown etiology commonly occurs in children, which cause severe chronic inflammatory disease involving single hemisphere. It always leads to intractable seizures, cognitive decline and progressive neurological deficits in the affected hemisphere.[28] Although the etiology of this sporadic disease is unclear, but some theory helps like, cytotoxic T cell reaction against the neurons was may be the one of reason in the pathogenesis of this disease.[29] MRI imaging plays a crucial role in diagnosis of this disease by excluding other causes and helps in monitoring of the disease progress. In MRI hyper intense areas with gyral thinning involving affected hemisphere with exvacuo dilatation of the ipsilateral ventricle.

HIV encephalitis occurs less commonly in recent era due to newer therapy. But commonly it can cause by cytomegalovirus and cryptococci. HIV is a neurotropic virus that enters the central nervous system (CNS) early in the course of infection. Up to 60% of patients with AIDS, neurologic manifestations are seen. In the era before the commencement of the usage of highly active antiretroviral therapy (HAART), neurologic disease was the first manifestation of symptomatic HIV infection in 10%–20% of patients.[30,31] HIV crosses the intact blood-brain barrier, and the virus has been cultured from the brain, nerve, and cerebrospinal fluid of patients at all stages of disease.

Our study is consistent with previous observations in the elusiveness of identifying etiological agents of encephalitis, but highlights the specific features for some common infection that helps in proper prognosis and remission of the disease.

Imaging findings coupled with the serology and clinical findings help in narrowing down the diagnosis to encephalitis in suspected patients.

Limitations of the study

- Serum IgM for specific virus was not done in all the cases of encephalitis.
- Diagnosis of these cases was made on MRI imaging appearances only.
- All suspected patients for encephalitis and those known patients who require follow up scans could not afford for MRI scan. Hence the cost of the modality and the patient affordability for MRI continues to be a drawback.

CONCLUSION

The causes of infectious encephalitis are many and varied, and accurate diagnosis is necessary for appropriate treatment and accurate prognostication.

Early diagnosis of encephalitis plays a crucial role in deciding the treatment regimen and has a decisive impact on its prognosis. Imaging findings play a pivotal role in the early detection and thus in the management of these patients suspected for encephalitis.

REFERENCES

1. Robin S, Ramful D, Le Seach' F, Jaffar-Bandjee MC, Rigou G, Alessandri JL. Neurologic manifestations of pediatric chikungunya infection. J Child Neurol. 2008;23(1): 1028–1035.
2. Granerod J, Cunningham R, Zuckerman M, et al. Causality in acute encephalitis: defining aetiologies. Epidemiol Infect 2010;138(6):783e800.
3. Skoldenberg B, Forsgren M, Alestig K, et al. Acyclovir versus vidarabine in herpes simplex encephalitis. Randomised multicentre study in consecutive Swedish patients. Lancet. 1984;2(1):707–11.
4. Chung SP, You JS, Lee HS. Use of the diffusion-weighted magnetic resonance imaging for early diagnosis of herpes simplex encephalitis in the ED:a case report. Am J Emerg Med. 2007;25(4):986.e5–986.e6.
5. Sawlani V. Diffusion-weighted imaging and apparent diffusion coefficient evaluation of herpes simplex encephalitis and Japanese encephalitis. J Neurological Sci. 2009;287(5):221–226.
6. Kennedy PG, Chaudhuri A. Herpes simplex encephalitis.

ISSN (Online): 2565-4810; (Print): 2565-4802 | ICV 2017: 69.52 |

J Neurol Neurosurg Psychiatry 2002;73(6):237–238.
7. Ishiguro N, Yamada S, Takahashi T, et al. Meningo-encephalitis associated with HHV-6 related exanthem subitum. Acta Paediatr Scand 1990; 79(7):987–989
8. Krueger GR, Klueppelberg U, Hoffman A, Ablashi DV. Clinical correlates of infection with human herpesvirus-6. In Vivo 1994; 8(2):457–485
9. Zimmerman RD, Russel EJ, Leeds NE. CT in the early diagnosis of herpes simplex encephalitis. Am J Roentgenol 1980; 134 (1): 61-6.
10. Cinque P, Cleator GM, Weber T, Monteyne P, Sindic CJ, van Loon AM. The role of laboratory investigation in the diagnosis and management of patients with suspected herpes simplex encephalitis: a consensus report. J Neurol Neurosurg Psychiatry 1996; 61(1): 339–345.
11. Teixeira J, Zimmerman RA, Haselgrove JC, Bilaniuk LT, Hunter JV. Diffusion imaging in pediatric central nervous system infections. Neuroradiology 2001;43(5): 1031–1039.
12. Kou K, Itoh M, Kawano Y. A Case Report of EB Virus-Induced Meningoencephalitis Associated with Brain MRI Abnormalities (basal ganglia) J Japan Peditr Sos. 1994;98(4):2052–9.
13. Young JY, Hyang LK. Transient Asymptomatic White Matter Lesions Following Epstein-Barr virus Encephalitis. Korean pediatric society. 2011;54(6):389–93.
14. Ono J, Shimizu K, Harada k, Mano T, Okada S. Characteristic MR Features of Encephalitis Caused by Epstein-Barr virus. Pediatr Radiol. 1998;28(1):569–70.
15. Grover D, News Halme W, Brink N. Herpes Simplex virus infection of the central nervous system in human immunodeficiency virus type 1 – infected patients. Int J STD AIDS 2004; 15 (9): 597-600.
16. Kumar S, Misra UK, Kalita J, et al. MRI in Japanese encephalitis. Neuroradiology 1997;39(6):180–84.
17. Leonard JR, ped encephalitis in infants and young children; a separate pattern of findings. Am J Roentgenol 2000; 174 (6): 1651-5.
18. Kalita J, Misra UK. Comparision of CT scan and MRI findings in the diagnosis of Japanese encephalitis. J Neurol Sci 2000;174(6):3–8
19. Shoji H, Kida H, Hino H, et al. Magnetic resonance imaging findings in Japanese encephalitis. White matter lesions. J Neuroimaging 1994;4(1):206–11
20. Ganesan K, Diwan A, Shankar SK, Desai SB, Sainani GS, Katrak SM. Chikungunya encephalomyeloradiculitis: Report of 2 cases with neuroimaging and 1 case with autopsy findings. AJNR Am J Neuroradiol. 2008;29(3):1636–7.
21. Wadia RS. A neurotropic virus (chikungunya) and a neuropathic amino acid (homocysteine) Ann Indian Acad Neurol. 2007;10(2):198–213.
22. Ganesan K, Diwan A, Shankar SA, Desai SB, Sainani GS, Katrak SM. Chikungunya encephalomyeloradiculitis: report of 2 cases with neuroimaging and 1 case with autopsy findings. AJNR Am J Neuroradiol. 2008;29(4):1636–1637.
23. Bhoi SK, Naik S, Kumar S, Phadke RV, Kalita J, Misra UK. Cranial imaging findings in dengue virus infection. J Neurol Sci. 2014;342(2):36–41.
24. Pal S, Sen K, Biswas NM, Ghosal A, Rousan Jaman SK, Yashavantha Kumar KY. Clinico-radiological profile and outcome of dengue patients with central nervous system manifestations: A case series in an Eastern India tertiary care hospital. J Neurosci Rural Pract. 2016;7(5):114–24.
25. Nadarajah J, Madhusudhan KS, Yadav AK, Gupta AK, Vikram NK. Acute hemorrhagic encephalitis: An unusual presentation of dengue viral infection. Indian J Radiol Imaging. 2015;25(6):52–5.
26. Tenembaum S, Chamoles N, Fejerman N. Acute disseminated encephalomyelitis: a long-term follow-up study of 84 pediatric patients. Neurology. 2002;59(1):1224–1231.
27. Baum PA, Barkovich AJ, Koch TK, Berg BO. Deep gray matter involvement in children with acute disseminated encephalomyelitis. AJNR Am J Neuroradiol. 1994;15(4):1275–1283.
28. Rasmussen T, Olszewski J, Lloydsmith D. Focal seizures due to chronic localized encephalitis. Neurology 1958.;8(6):435-445.
29. Bien CG, Bauer J, Deckwerth TL, Wiendl H, Deckert M, Wiestler OD, et al. Destruction of neurons by cytotoxic T cells: a new pathogenic mechanism in Rasmussen's encephalitis. Ann Neurol 2002;51(3):311-318.
30. LevyRM, Bredesen DE, Rosenblum ML. Neurological manifestations of the acquired immunodeficiency syndrome (AIDS): experience at UCSF and review of the literature. J Neurosurg 1985;62(4): 475–495.
31. de la MonteSM, Ho DD, Schooley RT, Hirsch MS, Richardson EP Jr. Subacute encephalomyelitis of AIDS and its relation to HTLV-III infection. Neurology 1987;37(4):562–569.

Source of Support: Nil; **Conflict of Interest:** None

Submitted: 10-10-2018; **Accepted:** 25-11-2018; **Published online**: 15-12-2018