

# Assessment of Normal Ocular Volume Using Magnetic Resonance Imaging

Surekha B<sup>1</sup>, Naveen D<sup>2</sup>, Rajendra T M<sup>3</sup>, G Sai Kiran<sup>4</sup>

<sup>1</sup>Assistant professor, Department of Radiodiagnosis, <sup>2</sup>Assistant professor, Department of Radiodiagnosis, <sup>3</sup>P G Resident, Department of Radiodiagnosis, <sup>4</sup>P G Resident, Department of Radiodiagnosis, PES Institute of Medical Sciences and Research, India

**Corresponding author:** Dr Naveen D, Assistant Professor, Department of Radiodiagnosis, PES Institute of Medical Sciences and Research, Kuppam – 517425, Chittoor Dt, A P, India

DOI: <http://dx.doi.org/10.21276/ijcmsr.2020.5.1.59>

**How to cite this article:** Surekha B, Naveen D, Rajendra T M, G Sai Kiran. Assessment of normal ocular volume using magnetic resonance imaging. International Journal of Contemporary Medicine Surgery and Radiology. 2020;5(1):A268-A270.

## A B S T R A C T

**Introduction:** Eyeball volume plays an important role in few ocular diseases like myopia, hypermetropia, presbyopia, macrophthalmia, microphthalmia, and astigmatism which affect the dimensions of the eye or its component may cause visual abnormalities. Diseases associated with decreased ocular volume like coat's disease, phthisis bulbi and persistent hyperplastic primary vitreous. Glaucoma may cause increase in ocular volume. Hence, it will be useful to know the effect of some diseases on eyeball volume and will help to plan treatment or surgical application. Study aimed to evaluate ocular volume in Indian population of different age groups using magnetic resonance imaging.

**Material and methods:** Data of consecutive 425 patients (850 Eyeballs) subjected to MRI brain were collected and analysed. At the level of lens the transverse and AP diameters of right and left eyeballs were measured and the data obtained from the both eye were compared in relation to size, gender and age

**Results:** The mean (mean  $\pm$  2 SD) ocular volume for right eye  $5967.17 \text{ mm}^3 \pm 1064.58 \text{ mm}^3$  and for the left eye was  $6025.4 \text{ mm}^3 \pm 1455.81 \text{ mm}^3$ . The mean ocular volumes were different for either eyeball and sex (in males the right eye was  $6057.79 \text{ mm}^3$ , left eye was  $5980.02 \text{ mm}^3$ ; while in females the right eye was  $5829.74 \text{ mm}^3$ , left eye was  $6141.4 \text{ mm}^3$ ). Mean transverse diameter of the eyeball is  $22.8 \pm 1.1 \text{ mm}$ . Mean antero posterior diameter of the eyeball is  $22.4 \pm 0.9 \text{ mm}$ .

**Conclusion:** The human adult eye approximately measures  $22.8 \pm 1.1 \text{ mm}$  (transverse) and  $22.4 \pm 0.9 \text{ mm}$  (axial) with no significant difference between sexes and age groups. These data can be helpful in ophthalmological, oculoplastic, and neurological practice. We noted that males had slightly bigger eyeballs size in comparison to females.

**Keywords:** Eyeball Volume, Magnetic Resonance Imaging

## INTRODUCTION

Eyeball volume (EV) plays an important role in few ocular diseases like myopia, hypermetropia, presbyopia, macrophthalmia, microphthalmia, and astigmatism which causes visual abnormalities by affecting the dimensions of the eye.<sup>1</sup> Coat's disease, phthisis bulbi and persistent hyperplastic primary vitreous are examples of diseases that is associated with reduced ocular volume.<sup>1</sup> Glaucoma may cause increase in ocular volume.<sup>1</sup> Hence, it will be useful to know the effect of some diseases on eyeball volume and will help to plan the treatment or surgical application.<sup>2</sup> Consequently, multimodality approach were made to determine the dimensions of the eyeball by using radiography, angiography, ultrasonography, computed tomography, magnetic resonance imaging, and photography.<sup>2,3</sup>

Gravimetric method was described by Wales to measure ocular volume,<sup>4</sup> but this method requires enucleating a diseased eye and extrapolating the volume of the normal eyes from the value obtained. Gravimetric method is not

practicable in most clinical situations due its destructive method. Intra-ocular lens (IOL) Master can also be utilized in ophthalmological clinics to determine eyeball axial length measurements from which EV can be calculated.<sup>1,2,5</sup>

Cross sectional imaging investigation have provided a noninvasive opportunity for volumetric quantification of the EV.<sup>2,6</sup> MRI offers optimal soft tissue contrast resolution and multiplanar capability to measure EV without using ionizing radiation.<sup>2,6</sup>

Study aimed to evaluate ocular volume in Indian population of different age groups using magnetic resonance imaging

## MATERIAL AND METHODS

In our prospective cohort study, 425 patients (850 eyeballs) who were referred to radiology department PES Institute of Medical Science and Research, Kuppam, Andhra Pradesh, between January 2019 and September 2019, for brain MR imaging were examined. The study was granted approval by the ethical committee of our institution.

The volume of eyeball was assessed using T1 - weighted axial series. The slices chosen for ocular measurements were mid-ocular section showing the maximum axial size of the eyeball, with the lens, optic nerve and insertions of the medial and lateral rectus muscles—Figure 1. Eyeball dimensions were obtained with transverse and anterior-posterior diameter of the eyeball. The total volume of the eyeball was calculated by using these two dimensions.

Exclusion criteria included ophthalmic pathologies or lesions such as tumours, fractures or bony lesions involving the facial bones/ orbital walls.

Even though the eyeball shape is slightly ellipsoidal, it is assumed to be spherical for volume estimation. These dimensions were recorded and the largest diameters were used to estimate the volume using the following formula:  $V = 4/3\pi r^3$  (cm<sup>3</sup>), where  $r = (AP + TR)/4$ ; AP = anterior-posterior diameter (cm) of the eyeball, TR = transverse diameter (cm) of the eyeball.

### RESULTS

The mean age of the patients was (42.8 ± 19.9) years with a median of 41 years. The youngest patient was 5 months old and the oldest 88 years. The ocular measurements were conducted in 233 males and 192 females. The male with mean age of 46.9 ± 19.3 years and mean age of females was 37.8 ± 19.5 years. The minimum age of the males was 2 years and the maximum age was 88 years while for the female minimum age was 5 months and the maximum 88 years (graph-1, table-1).

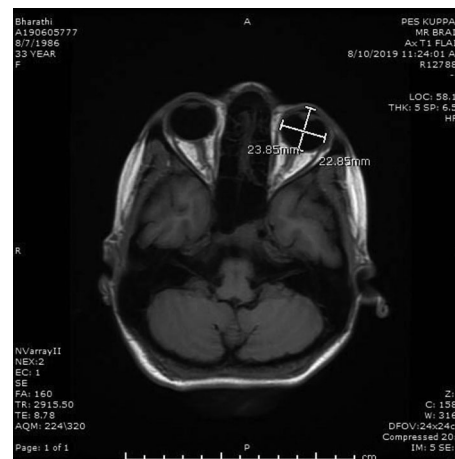Transverse diameter of the right eyeball size varied from 19 to 26.3 mm and left eyeball size 19 to 26 mm. Antero

posterior diameter of the left eyeball size varied from 17.4 to 26.0 and left eyeball size 17.6 to 25.5 mm.

In female the transverse diameter of eyeball varies from 19 to 26 mm. In female the antero posterior diameter of eyeball varies from 17.4 to 25.5 mm.

In males the transverse diameter of right eyeball 20 to 26.3 mm. In male the antero posterior diameter of eyeball varies from 19.1 to 26.0 mm.

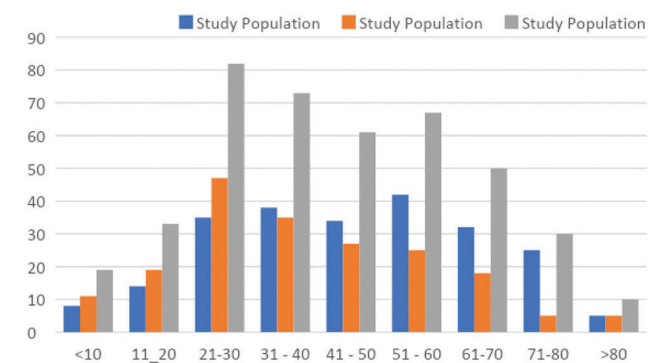
Mean transverse diameter of the eyeball is 22.8 ± 1.1 mm. Mean antero posterior diameter of the eyeball is 22.4 ± 0.9 mm. There was no significant difference in the transverse and AP diameter of the eyeball in relation to side and sex of population in our study (table-2).



**Figure-1:** T1W axial brain MRI at the level of the lens showing the sites of measurements.

Age	Male	Female	
<10	8	11	19
11_20	14	19	33
21-30	35	47	82
31-40	38	35	73
41-50	34	27	61
51-60	42	25	67
61-70	32	18	50
71-80	25	5	30
>80	5	5	10
Total	233	192	425

**Table-1:** Distribution of the population by age and sex



**Graph-1:** Age and sex distribution

Right eyeball volume (mm <sup>3</sup> )				Left eyeball volume (mm <sup>3</sup> )			
Age Group	Male	Female	Total (mean)	Age Group	Male	Female	Total (mean)
<10	5472.78	5033.72	5218.58	<10	5911.04	5574.83	5716.39
11=20	5967.95	5699.85	5813.59	11=20	5766.01	6227.55	6031.75
21-30	6325.09	6253.06	6283.81	21-30	6277.67	5995.09	6115.67
31-40	6364.84	6088.65	6232.42	31-40	6158.43	6105.42	6133.01
41-50	6231.61	5938.39	6101.82	41-50	6188.94	6292.39	6234.73
51-60	6206.34	5924.78	6097.22	51-60	6256.71	6092.13	6195.31
61-70	6081.44	5679.18	5943.11	61-70	5881.12	5991.21	5920.75
71-80	6343.29	5881.55	6266.33	71-80	5891.39	6809.49	6044.41
>80	5526.85	5968.51	5747.67	>80	5488.93	6185.13	5837.05
Total (Mean)	6057.79	5829.74	5967.17	Total (Mean)	5980.02	6141.47	6025.45

**Table-2:** The mean eyeball volume distributed subject sex and age group

The right eye mean (mean  $\pm$  2 SD) ocular volume was 5967.17 mm<sup>3</sup>  $\pm$  1064.58 mm<sup>3</sup> and for the left eye was 6025.45 mm<sup>3</sup>  $\pm$  1455.81 mm<sup>3</sup>.

The values of the minimum and maximum volume of the right eye 3157.86 mm<sup>3</sup> and 8946.73 mm<sup>3</sup>; minimum and maximum volume of the left eye 3210.16 mm<sup>3</sup> and 8332.73 mm<sup>3</sup>.

In males, the mean right ocular volume is 6057.79 mm<sup>3</sup> and left ocular volume is 5980.02 mm<sup>3</sup>.

In females, the mean right ocular volume is 5829.74 mm<sup>3</sup> and left ocular volume is 6141.47 mm<sup>3</sup>.

## DISCUSSION

In our study the ocular volume positively correlated with the age of the patients to about 50 years after which there was some reduction in size was observed. Males had slightly bigger eyeballs size in comparison to females, although not statistically significant level. This finding is in agreement with that of Chau et al.,<sup>7</sup> they stated that volumes of the eyeballs showed no significant gender effects. This may be because males' body habitus is generally larger than that of females with concomitant bigger size of the male organs compared to females. In another study conducted by Innesa Bekerman et al<sup>8</sup> on 250 adult patients (500 eyeballs) also showed no significant difference in size of eyeball in relation to gender and age groups.

In a study conducted by Joshua O Aiyekomogbon et al,<sup>9</sup> on a total of 340 globes of 170 patients in nigerian population on axial length of the eyeball showed significant difference in right and left globes. This study also showed higher values among male population. The mean axial length (AP) in our study population is 22.4  $\pm$  0.9 mm which is less than the value obtained in the above study conducted by Joshua O Aiyekomogbon et al which is 23.31  $\pm$  1.28 mm. This shows there are variations among different ethnic groups.

This study correlated length of the interzygomatic line (IZL) with some of the measurements of ocular structures and found majority of the variables showed statistically significant relationship with IZL. The facial size, which is represented by the length of the IZL, showed significant correlation with axial length of globe.<sup>9</sup> This observation is consonant with the larger head size in male as compared to female and there by difference in the size of the globe in males and females

Axial length (AP) is one of the important indicators of refractive state of the eyes. Eye with axial length < 22mm are classed as hyperopic and those > 26mm as myopic.<sup>10</sup>

Cross sectional imaging investigation have provided an noninvasive opportunity for volumetric quantification of the eyeball volume. MRI has excellent soft tissue contrast resolution and multiplanar capability without the use of ionizing radiation. MR imaging is also very helpful in assessing the shape of soft tissue like the eyeball. Eyeball volume plays an important role in some ocular diseases such as macrophthalmus, buphthalmus, microphthalmos, etc. Congenital glaucoma is a developmental disorder which causes obstruction of intraocular fluid drainage, so that there will be increase in eye pressure and lead to enlargement of globe.<sup>2</sup> Hence, it will be useful to know the effect of some diseases on eyeball volume and will help to plan the treatment

or surgical application.<sup>2</sup>

## CONCLUSION

This study gives the normal volume of eyeball in different age group in Indian population and with a hope that these values can be used for normal reference.

## REFERENCES

1. Igbinedion B O, Ogbeide O U. Measurement of normal ocular volume by the use of computed tomography. *Niger J Clin Pract* 2013;16:315-9
2. Ibinaiye PO, Maduforo C O, Chinda D. Estimation of the Eyeball Volume on Magnetic Resonance Images in Zaria, Nigeria. *Sub-Saharan Afr J Med* 2014;1:82-5
3. Misra M, Rath S. Computed tomographic method of axial length measurement of emmetropic Indian eye a new technique. *Indian J Ophthalmol* 1987; 35:17-21
4. Wales RC. Ocular measurement by simple gravimetric methods. *Invest Ophthalmol Vis Sci* 1977; 16(2):580-2.
5. Foteda R, Wang JJ, Burlutsky G, Morgan IG, Rose K, Wong TY. Distribution of axial length and ocular biometry measured using partial coherence laser interferometry (IOL Master) in an older white population. *Ophthalmology* 2010; 117(1):417-23.
6. Acer N, Demir M, Ucar T, Pekmez H, Goktas A. Estimation of the Eyeball and Orbital Volume Using the Cavalieri Principle on Computed Tomography Images. *Balkan Med J* 2011; 28(3):184-8.
7. Chau A, Fung K, Yp M. Orbital development in Hong Kong Chinese subjects. *Ophthalmic Physiol Opt* 2004;24(5):436-9.
8. Inessa Bekerman, Paul Gottlieb, Michael Vaiman. Variations in eyeball diameters of the healthy adults. *Journal of ophthalmology* 2014;503645.
9. Joshua O. Aiyekomogbon, Abdulkadir L. Rafindadi. Ocular Axial Length Measurement Among Normal Adults Using Magnetic Resonance Imaging. *Nigerian Journal of Ophthalmology* 2017;25(4):6-10.
10. Mangat S, Kumar BV, Prasad S. Presentation on Theme: 'Biometric Accuracy in High Hypermetropes And Myopes. Arrowe Park Hospital, Wirral University Hospital NHS Trust No financial.' - Presentation Transcript. Available from: <http://slidegur.com/download/309314#text>. [Last accessed 2016 Mar 21].
11. Ibinaiye PO, Maduforo C O, Chinda D. Estimation of the Eyeball Volume on Magnetic Resonance Images in Zaria, Nigeria. *Sub-Saharan Afr J Med* 2014;1(2):82-5.

**Source of Support:** Nil; **Conflict of Interest:** None

**Submitted:** 29-01-2020; **Accepted:** 16-02-2020; **Published online:** 23-03-2020