ORIGINAL RESEARCH ARTICLE

MR Evaluation in non Traumatic Chronic Wrist Pain

Vivek Chail[1], Abhijit N[2], Rajan Balasubramanyam[3], Roohi Singh[4], Riyanka Chail[5]

[1]Assistant Professor, Department of Radio Diagnosis, Dr. B.R. Ambedkar Medical College and Hospital, Kadugondanahalli, Bangalore 560045, Karnataka, [2]Resident, Department of Radio Diagnosis, Dr. B.R. Ambedkar Medical College and Hospital, Kadugondanahalli Bangalore 560045, Karnataka, [3]Professor and Head of Department, Department of Radio Diagnosis, Dr. B.R. Ambedkar Medical College and Hospital, Kadugondanahalli Bangalore 560045 Karnataka, [4]Consultant, Department of Radiologist, Medall Clumax Diagnostics, Old No 66 & New No 1, 2nd Main Road, Bashyam Circle Sankey Cross Road Malleswaram, Gayathri Devi Park Extension, Kodandarampura, Sadashiva Nagar Bangalore 560003 Karnataka, [5]Assistant Professor, (Physiology), BGS Global Institute of Medical Sciences, No. 67, BGS Health & Education City, Uttarahalli Road, Kengeri, Bangalore 560060 .Karnataka, India

Corresponding author: Dr. Vivek Chail, House No.9, Site. No.40-41, Chail Bhawan, 6th cross Dead End, C.L.Ramiah Layout, Shampura, Post Office R.T. Nagar, Bangalore 560032, Karanataka, India

DOI: http://dx.doi.org/10.21276/ijcmsr.2020.5.1.18

How to cite this article: Vivek Chail, Abhijit N, Rajan Balasubramanyam, Roohi Singh, Riyanka Chail. MR evaluation in non traumatic chronic wrist pain. International Journal of Contemporary Medicine Surgery and Radiology. 2020;5(1):A79-A84.

ABSTRACT

Introduction: Wrist pain is a common clinical complaint that presents with a diagnostic challenge to the physician because of complexity of bony articulations and surrounding soft tissue. As wrist pain can be caused by many factors, diagnosing the exact cause can be difficult. Magnetic resonance imaging, with its exquisite soft-tissue contrast and multiplanar capabilities, can help determine the causes of wrist pain and help assess the extent and severity of disease. Our main objective was to study the epidemiology and most common causes of non-traumatic chronic wrist pain in the South Indian population and to study the spectrum of MRI features in those patients.

Material and methods: Prospective descriptive study was done on 30 patients of both sex and age ranging from 11 to 70 years who presented with non-traumatic chronic wrist pain were selected for study and analyzed.

Result: In our study, we found painful wrist is fairly equally common in almost age groups between 21 years to 60 years and is slightly more prevalent in the females compared to males We found infective and inflammatory causes formed the bulk of cases (~70%). Degenerative and inflammatory diseases were more common than infective disorders (36.7% as compared to 33.3%). Among inflammatory diseases, degenerative arthritis was the most common, followed by inflammatory tenosynovitis and rheumatoid arthritis. Bony lesions and soft tissue mass lesions formed the third-largest group (20%). The most common lesions included ganglion cysts and hemangiomas. We found fewer cases of avascular necrosis (6.7%) and carpal tunnel syndrome (3.7%).

Conclusion: Early timely diagnosis by MRI not only helps in management but also help reduce long term disability. There has been a trend towards inflammatory/degenerative disorders due to the changing lifestyle and delayed presentation in developing countries.

Keywords: MRI Wrist, Non-Traumatic Wrist Pain, Chronic Wrist Pain.

INTRODUCTION

Wrist pain is a common clinical complaint that presents with a diagnostic challenge to the physician because of complexity of bony articulations and surrounding soft tissue.As wrist pain can be caused by many factors, diagnosing the exact cause can be difficult. Magnetic resonance (MR) imaging, with its exquisite soft-tissue contrast and multiplanar capabilities, can help determine the causes of wrist pain in ambiguous or clinically equivocal cases, as well as help, assess the extent and severity of disease.[1]

Etiopathogenesis

The causes of wrist pain are diverse. It is useful to first establish whether the pain is due toa traumatic or non-traumatic etiology. In the case of trauma, ligament rupture/tear, tendon injury, and fracture(s) need to be investigated.[2]

Non-traumatic etiologies of wrist pain can vary. It is useful to characterize the pain andinquire about systemic symptoms. Abrupt onset of pain can indicate infection, arthritisor osteonecrosis. Gradual onset of symptoms are more characteristic of tenosynovitis,nerve entrapment syndromes or arthritis.[2.]

A person's age and gender might help to focus the diagnosis. Younger patients (less than 40years) are more prone to post-traumatic carpal injuries, whereas the older populationis more susceptible to systemic diseases and degenerative processes that involve the wristjoint. Osteoarthritis and rheumatoid arthritis seem to affect women more frequently than men.[2]

Causes of non traumatic wrist pain can be broadly classified are as follows[3]

ISSN (Online): 2565-4810; (Print): 2565-4802 | ICV 2018: 86.41 |

Degenerative Inflammatory Disease

- Connective Tissue Diseases- Rheumatoid arthritis, systemic erythematous lupus
- Metabolic Disease-gout, pseudo-gout, Hyperparathroidism, chondrocalcinosis
- Tendonitis, Tenosynovitis, Repetetive Strain Injury
- Chondritis/ Primary Arthrosis

Infective Disorders

- Common Bacterial/ Atypical Agent, granulomatous disease

Neoplastic Disorders

- Ganglia (extraosseous/ intraosseous/ occult),Tendon cysts
- Bone tumours- enchondroma, osteoid osteoma, chondromatosis
- Soft tissue tumours- pigmented villo nodular synovitis, giant cell tumour
- Malignant tumours.
- Metastases

Congenital and developmental disorders

- Simple osseous cyst
- Madelung deformity
- Muscular abnormalities- extensor brevis manus
- Carpal coalition

Neurological disorders

- Traumatic
- Compressive- Carpal tunnel syndrome

Imaging investigations

Unless otherwise indicated by clinical findings, the initial radiographic examination should consist of three views: standard posteroanterior (PA), oblique (PA oblique or AP oblique), and lateral views. The conventional radiographs are examined for bony abnormalities (fractures, cortical interruption, degree and pattern of mineralization) and the width and symmetry of joint spaces.[2]

When clinical examination suggests superficial involvement, and extraarticular pathology is suspected, an ultrasound examination should be the next step. Musculoskeletal ultrasound is a quick and easy method of excluding soft tissue abnormalities, particularly tendon damage, ganglia, and synovial cysts. Although it allows for dynamic studies and bilateral comparisons with low patient discomfort, the quality and interpretation of ultrasound findings are operator dependent, and therefore its use is limited.[2]

The computed axial tomography (CAT) scan has been used in the diagnosis of carpal pathology, but its only advantage is a better definition of the static alterations of the relationships between the carpal bones and the distal extremities of the radius and the ulna.[2]

If the history and physical examination (clicking or snapping) suggest that the patient's problems arise from interosseous ligamentous or TFCC injuries, cineradiography or an arthrogram under fluoroscopic control may be done.[2]

MRI is the most effective method for helping determine cause of wrist pain by demonstrating a broad spectrum of abnormalities, including those of bone, cartilage, ligaments and tendon. MRI is useful in detection, characterization and staging of osseous injury and disease. MRI can demonstrate cartilage loss in arthropathies and its superior soft tissue contrast makes it method of choice for evaluating the synovial processes. 3T MRI can depict small interosseous ligaments. Tendinitis, tenosynovitis, ganglia, anatomic variants can be diagnosed and accurately assessed by MR imaging.[1.]

Radionuclide Imaging Bone scans are very sensitive but not particularly specific. A bone scan can be helpful as a screening test. Scintigraphy can be useful in assessing for the presence of the early phases of reflex sympathetic dystrophy; osteonecrosis of the scaphoid, lunate, and capitate; arthrosis; occult fractures; or any other pathologic condition that causes an increase in bone turnover.[4.]

SPECT/CT proved to be the most helpful imaging modality in patients with non-specific wrist pain. The method was found reliable, providing high interobserver agreement, being outperformed by MRI only concerning the typification of lesions. It is beneficial to integrate SPECT/CT into the diagnostic imaging algorithm of chronic wrist pain[5], and its superior soft-tissue contrast makes

MR imaging of wrist joint[6]

Bones and cartilage: Occult fractures are detected as linear, low signal intensity on the T1-weighted sequence with surrounding bone marrow edema. Areas of bone contusion are differentiated mainly by the absence of a clear fracture line. Typical areas include the scaphoid, the tubercle of trapezium (radial-sided pain), the hook of the hamate (ulnar/volar-sided pain) and the distal radius.

Avascular necrosis (AVN) of the lunate (Kienbock's disease) is characterized initially by high signal intensity on fluid sensitive sequences, with low signal intensity on all sequences later in disease progression. A typical coronal plane fracture and bone fragmentation may follow, with further progression of OA changes of the carpus. Enhancement with IV contrast is associated with viability of the fragment, while low signal on all sequences (corresponding to sclerosis on radiographs and CT) is compatible with established necrosis

Ligaments: The scapholunate ligament and lunotriquetral ligament is the most relevant intrinsic ligament of the wrist that can be assessed with MRI. Disruption or indistinction of the fibers indicates a full-thickness tear of the component. Signal changes along their topography in cases of post-traumatic injury may indicate sprain.

Triangular fibrocartilage complex (TFCC): Owing in part to these characteristics, injuries of the TFC proper are confidently depicted by MRI; they include degenerative signal changes,non-communicating defects (or partial tears) of the surfaces, and communicating defects (full-thickness tears).

Tendons: The flexor and extensor tendons present typical low signal intensity and constant diameter on all sequences. Tendinopathy presents as signal and thickness changes on MRI, and may progress to partial- or full-thickness tears, with or without associated fluid and synovitis of the sheath(tenosynovitis. While most cases of tenosynovitis are due to overuse/degenerative changes, other etiologies such as gout, rheumatoid arthritis, amyloidosis, septic and

ISSN (Online): 2565-4810; (Print): 2565-4802 | ICV 2018: 86.41 |

mycobacterial tenosynovitis and sarcoidosis remain in the differential diagnosis.

Nerves: Main findings in cases of compressive neuropathy (carpal tunnel syndrome) are thickening of the nerve proximal to the entrance of the tunnel with associated increased signal on the fluid-sensitive sequences. The role of MRI in carpal tunnel syndrome is to exclude a potential cause for the symptoms, such as flexor tenosynovitis, or masses/cysts within the carpal tunnel.The ulnar nerve travels through the canal of Guyon (ulnar nerve tunnel) along the ulnar aspect of the wrist and is the most ulnar structure in the canal, in close proximity to the pisiform and hook of the hamate. Neuropathy may be associated with ganglia and masses within the tunnel, compression due to accessory muscle slips around the nerve, or even fractures or stress injuries of the hook of the hamate.

Arthritis: Osteoarthritis may incidentally be seen on MRI as areas of chondropathy, bone-marrow edema, cysts, and sclerosis, as well as areas of osteophyte formation, joint effusion and synovial reaction. Internal derangements such as SLL or TFC tears may be associated. Large field-of-view MRI of the hands is employed in many centers to investigate and stage cases of inflammatory arthropathies such as rheumatoid and psoriatic arthritis.
Findings include synovitis and marrow edema, bone erosions, periarticular cysts and tenosynovitis. Investigating inflammatory arthropathies warrants the use of intravenous gadolinium. Acute and subacute carpal infections and tenosynovitis are characterized by synovitis and erosions, as well as by capsular and soft-tissue edema in variable degrees, and also warrant the use of IV contrast.

Ganglia: A ganglion is defined as a cyst in contact with a joint capsule or tendon sheath. It contains thick, gelatinous material and a thin capsule, without internal synovial lining. Ganglia may be connected to injured ligaments or demonstrate intra-osseous extension.They present with high signal intensity on fluid-sensitive sequences and low signal on T1-weighted sequences, and they may be complex, with debris, loculations or septations.
Current study aimed to know the epidemiology and most common causes of non-traumatic chronic wrist pain in the South Indian population and to study the spectrum of MRI features in patients presenting with non-traumatic chronic wrist pain.

MATERIAL AND METHODS

This was a prospective study covering 30 patients in the Department of Radiology, Ambedkar Medical College and Hospital, Bangalore over two years extending from Jan 2018 to Dec 2019. Ethical clearance was obtained from a board chaired by the head of the institute. Informed written consent was taken from patients after explaining the risks and benefits of procedure.

Inclusion criteria

- Patients of both sex and all groups were included in this study who were referred for MRI wrist with complaints of chronic wrist pain more than6 months duration.

Exclusion criteria

- Patients with MRI incompatible implants, cardiac implants or foreign bodies.
- Pregnant women.
- Patients having a previous history of wrist trauma.

Method of data collection

All patients underwent MR wrist according to standard techniques.

Technique / methodology

MR imaging data was interpreted from images obtained on Toshiba 1.5T MRI system and Siemens 1.5 T MRI system, using 8 channel phased array coil systems. The sequences evaluated were T1 axial and coronal, T2 coronal and axial, PD FAT SAT in axial, coronal and sagittal, T1 TIRM coronal and T1 VIBE coronal. FOV ranging from 8 to 12 cm. Slice thickness ranging from 1mm to 3 mm and a matrix of 256 x 256.

STATISTICAL ANALYSIS

Descriptive statistics was performed for study variables as frequency and percentage Graphs were made through Microsoft Excel.

RESULTS

In our study there were 30 patients ranging from 11-20 yr to 61-70 years group(Chart no.1). A maximum number of patients were in the age group 21-30 yr, a total of 7 patients (23.3%). Three were 6 patients (20%) in each group of 31-40

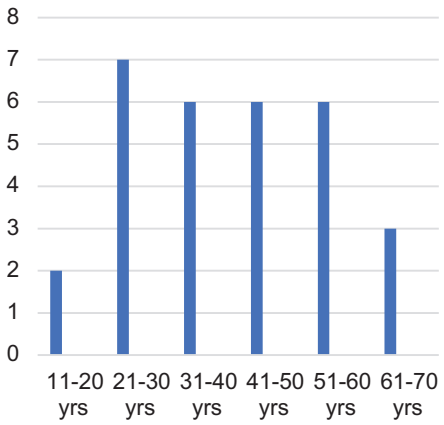

Graph-1: Age distribution

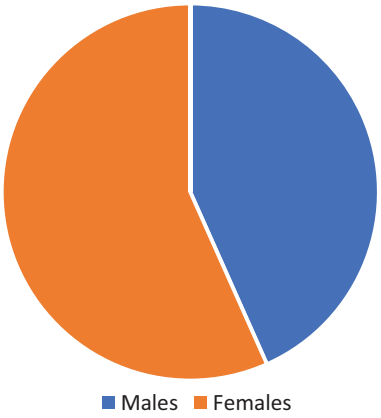

Graph-2: Sex distribution

ISSN (Online): 2565-4810; (Print): 2565-4802 | ICV 2018: 86.41 |

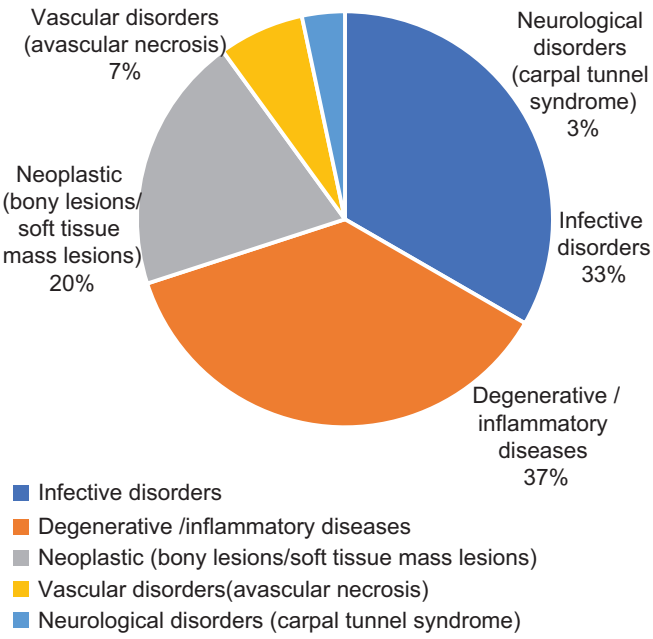

Graph-3: Etiology

CASE NO.1

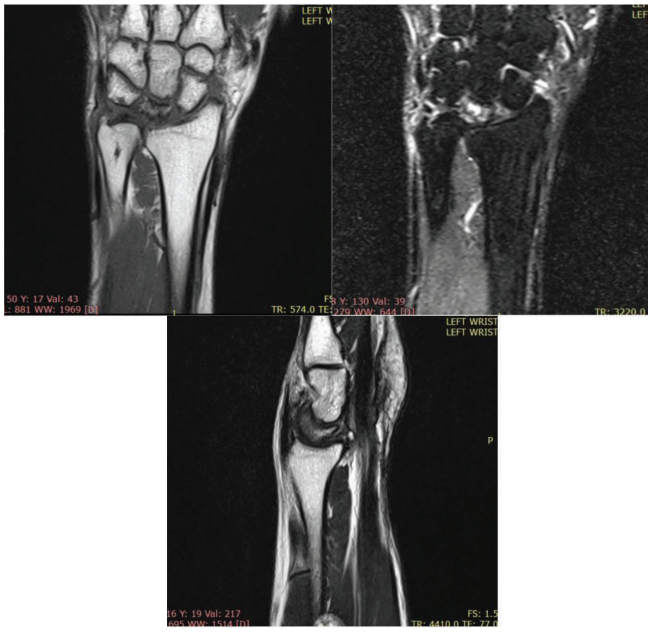

Figure-1A: T1 COR, IB:T1 TIRM COR, IC: T2 SAG; Kienbock Disease: Lunate appears small &mildy collpased and shows abnormal signal intensity in form of T1 hyponintensity and T2 hyperintensity. Mild marrow edema with cystic changes are also appreaciated in T1 TIRM sequence.

yrs, 41-50 yrs and 51-60 yrs. There were 2 patients (6.7%) in age group 11-20 yrs and 3 patients (10%) in age group 61-70 yrs (graph-1).

Out of 30 patients (graph-2) there were 13 males (43.3%) and 17 females (56.7%).

In our study we found a varied etiology of non-traumatic wrist pain (graph-3). There was a total of 11 cases (37%) of degenerative and inflammatory diseases, 10 cases (33%) of infective disorders, 6 cases (20%) of neoplastic lesions, 2

CASE NO.2:

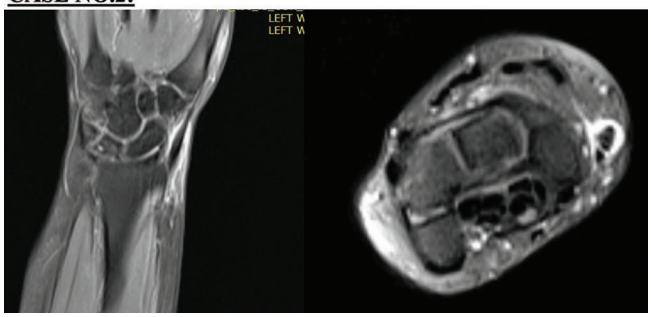

Figure-2: PD FATSAT COR 2B:PD FATSAT AXIAL;DE QUERVIAN TENOSYNOVITIS: First dorsal extensor compartment tendons (Abductor pollicis longus and externsor pollicis brevis) shows enlargement with altered signal changes and peritendinous fluid collection.

CASE NO.3

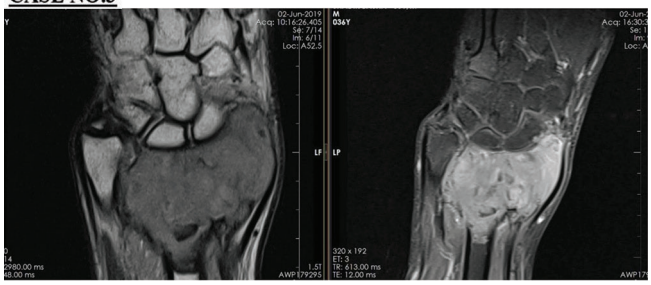

Figure-3: PD COR, 3B: PD FAT SAT COR:Gaint Cell Tumour - Subarticular expansile lesion in distal metaphysio-epiphyseal region radius with cortical breach in medial aspect.

CASE NO.4

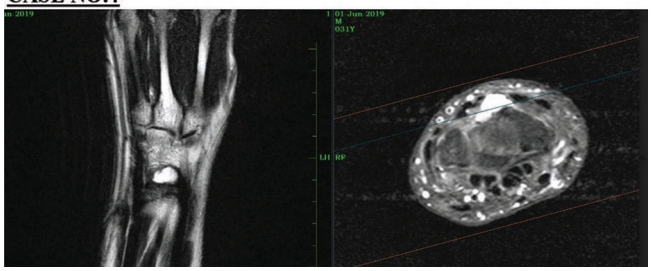

Figure-4: 4A: T2 COR, 4B: PDFAT AXIAL: Ganglion Cyst in dorsal aspect of wrist joint extending between second and third extensor compartment muscles.

CASE NO.5

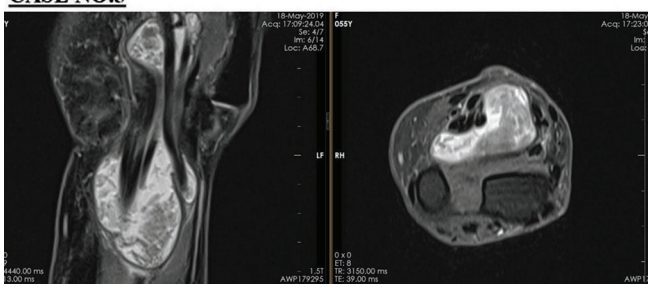

Figure-5: T1 POST CONTRAST COR, 5B: T1 Post contrast axial: Giant cell tumour of tendon sheath: Well defined lobulated dumb bell shaped heterogenously enhancing lesion insinuating between the flexor muscles tendons. No involvement of underlying bones.

CASE NO.6

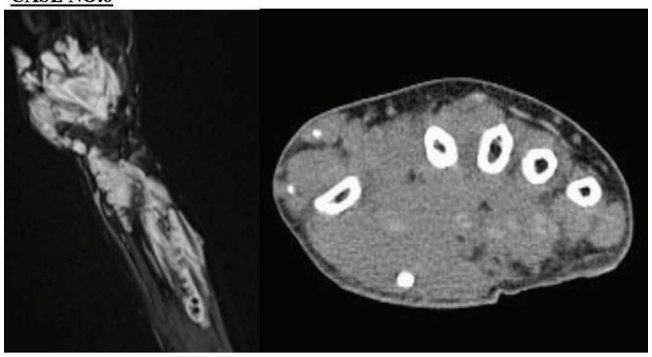

Figure-6: 6A: STIR COR, 6B: NCCT axial: Soft tissue hemangioma: Lobulated hyperintense lesion invovling volar aspect of foream, wrist and hand. Correlative CT section showed small hyperdense foci, representing phleboliths.

CASE NO.7:

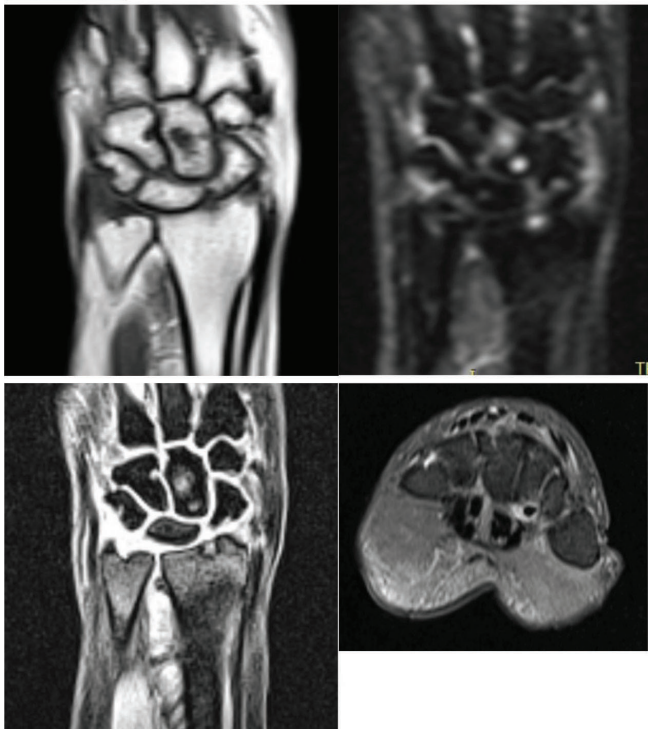

Figure-7: T1 COR, 7B: T1 TIRM COR, 7C: T1 VIBE COR, 7D: PD FAT AXIAL: Rheumatoid Arthritis: Erosive changes with synovitis are noted in radiocarpal, ulnocarpal and intercarpal joints and associted tensoynovitis of flexor carpi radialis tendon.

vascular disorders (7%) and 1 neurological disorder (3%).

Degenerative and inflammatory diseases were found to be the most common cause. Among inflammatory diseases, degenerative arthritis formed the largest group. There were two cases of inflammatory arthritis (Rheumatoid arthritis) and three cases of inflammatory tenosynovitis. Infective causes were the second most common cause. Among infective causes, bacterial causes were most common. There was one case of tuberculous arthritis. Neoplastic etiology which concluded bony lesions and soft tissue mass lesions formed the third-largest group. There were two cases of ganglion cyst and hemangioma, one case each of Giant cell tumor of radius

CASE NO.8

Figure-8: 8A: T1 COR, 8B: T1 POST CONRAST, 8C:T1 TIRM COR: Infective Arthritis: Erosive chages are seen invovling radio-carpal and ulno carpal joints with joint effusion and surrounding soft tissue edema.

CASE NO.9

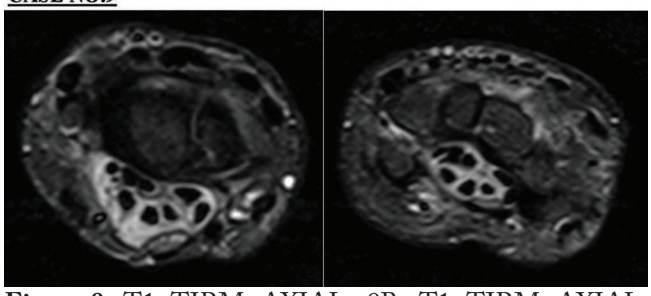

Figure-9: T1 TIRM AXIAL, 9B: T1 TIRM AXIAL: Carpal Tunnel Syndrome: Edema of carpal tunnel is noted with enlargement and increased signal intensity in median nerve at level of distal radio-ulnar joint. There is flattening of median nerve distally at the level of hamate in keeping with carpal tunnel syndrome.

and flexor tendon sheath GCT. Among vascular causes, we found 2 cases of avascular necrosis of lunate. Neurological causes were the least common which included one case of carpal tunnel syndrome.

DISCUSSION

There has been an increase in awareness of need for MRI scan for evaluation of patients presenting with non-traumatic chronic wrist pain. MRI wrist is an important investigation to make a confirmed diagnosis in most cases of non-traumatic chronic wrist pain which allows for providing a more focused and curative treatment.

In our study, we found chronic painful wrist was fairly equally common in almost age groups between 21 years to 60 years with a decreased incidence in extremes of age. Chronic painful wrist was slightly more prevalent in the female population as compared to the male population.

In our study, we found inflammatory and infective causes

ISSN (Online): 2565-4810; (Print): 2565-4802 | ICV 2018: 86.41 |

formed the bulk of cases (approximately 70%) presenting with the painful wrist. Degenerative and inflammatory diseases were more common than infective disorders (36.7% as compared to 33.3%). Bony lesions and soft tissue mass lesions formed the third-largest group (20%). Most common lesions were ganglion cysts and hemangiomas.We found fewer cases of avascular necrosis (6.7%) and carpal tunnel syndrome (3.7%).

According to Mohameed R El Kholy et al[7], avascular necrosis was the most common cause of non-traumatic wrist pain. Neoplasm and arthritis were the least common pathological findings.

Richard M Van Vugt et al[8] subdivided chronic wrist pain into pain of probable intra-articular or extra-articular origin and developed an algorithm for diagnosis. Tenosynovitis and repetitive strain injury constituted the largest group.

Limitation of study: Study group had lesser number of patients so results needs to be reviewed on a larger subset of population.

CONCLUSION

There has been an increase in awareness of need for MRI scan for evaluation of patients presenting with non-traumatic chronic wrist pain. MRI wrist is an important investigation to make a confirmed diagnosis in most cases of non-traumatic chronic wrist pain which allowed for providing a more focused and curative treatment.

Degenerative and inflammatory diseases were the most common cause of non-traumatic chronic wrist pain, followed closely by infective causes. A new trend which was not seen in earlier studies, possibly due to changing lifestyles and delay in patient presentation. Neoplastic causes which included bony lesions and soft tissue mass lesions were next only to infective causes. Non-traumatic chronic wrist pain was fairly common in all age groups, withslightly more preponderance in females.

REFERENCES

1. Oneson, S., Scales, L., Erickson, S. and Timins, M. MR imaging of the painful wrist. RadioGraphics, 1996;16(2):997-1008.
2. Stacommunications.com.(2019).[online]Availableat: http://stacommunications.com/journals/diagnosis/images/diagnosispdf/august01/bhandari.pdf [Accessed 23 Dec. 2019].
3. Atzei, A. and Luchetti, R. (n.d.). Clinical Approach to the Painful Wrist. Wrist Arthroscopy, pp.185-195.
4. Nagle, D. Evaluation of Chronic Wrist Pain. Journal of the American Academy of Orthopaedic Surgeons 2000; 8(1);45-55.
5. Huellner, M., Bürkert, A., Strobel, K., Pérez Lago, M., Werner, L., Hug, U., von Wartburg, U., Seifert, B. and Veit-Haibach, P. Imaging Non-Specific Wrist Pain: Interobserver Agreement and Diagnostic Accuracy of SPECT/CT, MRI, CT, Bone Scan and Plain Radiographs. PLoS ONE 2013;8(12):e85359.
6. Sampaio, M. and Kolanko, N. (2019). Article - MRI of the wrist. [online] Appliedradiology.com. Available at: https://appliedradiology.com/articles/mri-of-the-wrist [Accessed 2 Dec. 2019].
7. Hemeeda, Y., El-Kholy, M. and Maaly, M. (2015). Role of MRI in evaluation of painful wrist joint. Menoufia Medical Journal 2015;28(2):503.
8. Van Vugt, R., Bijlsma, J. and van Vugt, A. Chronic wrist pain: diagnosis and management. Development and use of a new algorithm. Annals of the Rheumatic Diseases 1999;58(11):665-674.
9. Zlatkin, M., Chao, P., Osterman, A., Schnall, M., Dalinka, M. and Kressel, H. Chronic wrist pain: evaluation with high-resolution MR imaging. Radiology 1989;173(3):723-729.
10. Mohamadi, A., Claessen, F., Ozkan, S., Kolovich, G., Ring, D. and Chen, N. Diagnostic Wrist Arthroscopy for Nonspecific Wrist Pain. HAND, 2016;12(2):193-196.
11. Shehab, R. and Mirabelli, M. (2019). Evaluation and Diagnosis of Wrist Pain: A Case-Based Approach. [online] Aafp.org. Available at: https://www.aafp.org/afp/2013/0415/p568.html [Accessed 2 Dec. 2019].

Source of Support: Nil; **Conflict of Interest:** None

Submitted: 26-12-2019; **Accepted:** 21-01-2020; **Published online**: 17-02-2020