Case Report

Rhinoorbital Mucormycosis after Atypical Pneumonia due to SARS-COV 2

Angélica E. Espinosa[1], Norberto E. Guerrero[2], Mario B. Rueda[3], Erasmo González[4]

[1]Department of Otolaryngology, Centro Médico ISSEMyM Toluca, Metepec, México, [2]Department of Otolaryngology, Centro Médico ISSEMyM Toluca, Metepec, México, [3]Department of Otolaryngology, Centro Médico ISSEMyM Toluca, Metepec, México, [4]Department of Otolaryngology, Centro Médico ISSEMyM Toluca, Metepec, México

Corresponding author: Angélica Espinosa, Department of Otolaryngology, Centro Médico ISSEMyM Toluca, Avenida Baja Velocidad KM. 284, 52170, Metepec, México.

DOI: http://dx.doi.org/10.21276/ijcmsr.2021.6.3.11

How to cite this article: Angélica E. Espinosa, Norberto E. Guerrero, Mario B. Rueda, Erasmo González. Rhinoorbital mucormycosis after atypical pneumonia due to SARS-COV 2. International Journal of Contemporary Medicine Surgery and Radiology. 2021;6(3):C45-C48.

A B S T R A C T

Introduction: Patients who are at an ICU or those who have immunosuppression are more affected by opportunistic microorganisms than those who are not in this scenario.

Case report: We present a female patient who came though COVID and posteriorly rhinoorbital mucormycosis while she was hospitalized. She was then admitted at our hospital, Amphotericin B was administered and then an endoscopical sinus surgery was performed. She continued hospitalized for treatment and was posteriorly discharged. After the sinus surgery we sent tissue to microscopic analysis, visualizing non-septate hyphae and angioinvasion, characteristic of Mucormycosis. She was later assessed by the Ophthalmology service, who performed an eye ultrasound, visualizing an entire eyeball. She's actually in follow-up by our service, Ophthalmology and Infectous diseases' service.

Conclusions: Due to immunosuppression by COVID and chronic diseases, mucormycosis may be increased in the future. Early diagnosis and treatment are associated with better results.

Keywords: Rhinoorbital Mucormycosis, Atypical Pneumonia, SARS-COV 2

INTRODUCTION

Mucormycosis is a rare and emergent fungal infection, with high morbidity and mortality. Due to the rarity of the disease, most of the available data con epidemiology diagnosis and treatment come from reports and case series.

This is an angioinvasive fungal infection due to fungi of the order Mucorales. Depending on the clinical presentation, it is classified as rhinocerebral, pulmonary, cutaneous, gastrointestinal, disseminated or other, however, it also includes rare forms, such as endocarditis, osteomyelitis, peritonitis, renal, etc.[1]

Fungal infections have increased considerably in recent years, due to advances and the intensity of medical care, which can weaken patients' immunity.[2]

COVID 19, which is the disease caused by the new coronavirus (SARS-COV 2), can be associated to a significant and sustained lymphopenia that compromises the immune system, especially in the most severe cases, making individuals more susceptible to bacterial and fungal infections that may be associated with pre-existing morbidity such as diabetes mellitus, obstructive chronic pulmonary disease and other chronic diseases.[3,4]

The following is a clinical case of a 43-year-old patient with type 2 diabetes mellitus of 7 years of diagnosis, who presented with COVID 19 with subsequent advanced airway management for 48 hours and stay in the intensive care unit for 5 days. During her hospitalization, she suffered from rhinoorbital mucormycosis, which later merited antifungal management and surgical treatment by our department.

CASE REPORT

A 43-year-old female patient with a history of type 2 diabetes mellitus of 7 years of diagnosis under treatment with metformin / linagliptin, who is admitted to the emergency department of a second-level hospital in the city of Toluca, State of Mexico due to presenting COVID 19, which required invasive mechanical ventilation for 48 hours, with a stay in the intensive care unit for 5 days. During her hospital stay, pain and facial fullness were added, as well as left nasal obstruction and an ulcer with necrotic characteristics on the nasal pyramid, predominantly on the left; loss of ipsilateral vision was added later.

On physical examination, we found an area of necrosis on the dorsum and left nasal lateral wall which affects the medial canthus, approximately 5x5 cm with poorly defined borders that limit the ipsilateral ocular opening. (Figure 1).

The anterior rhinoscopy reveals necrotic crusts on all the walls of the nasal cavity, as well as the absence of turbinates.

A soft and hard palate with an area of left necrosis is also observed, mucopurulent secretion is also observed through

ISSN (Online): 2565-4810; (Print): 2565-4802 | ICV 2019: 98.48 |

Figure-1: Clinical presentation showing necrotic area over the dorsum and medial cantus.

Figure-2: Externally necrotic scab removal.

Figure-3: The tissues are approximated and sutured by planes and the procedure is terminated without apparent complications.

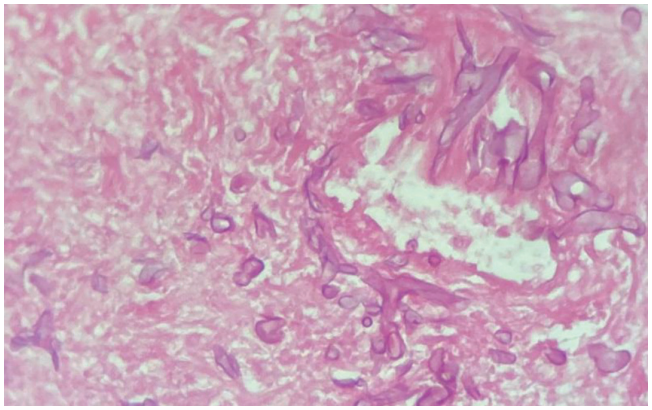

Figure-4: Non-septate hyphae with vascular invasion.

the ocular cavity, immobility of extrinsic muscles of the eye, as well as loss of visual acuity, with loss of sensitivity of the ophthalmic and maxillary branch of the trigeminal nerve.

She was evaluated by the Ophthalmology service of the medical center where she was treated, performing periodic eye ultrasounds commented that the eyeball was intact, with no evidence of vitreitis, periorbital cellulitis, posterior uveitis, or alteration in the choroid or orbital apex.

Computed tomography of the nose and paranasal sinuses without contrast was obtained at her admission, whereas we visualized frontal sinus, maxillary, sphenoidal and left anterior and posterior ethmoidal cells aerated, completely occupied by isodense image to soft tissues, middle and inferior turbinate, unciform process, infundibulum and left mastoid antrum partially lysed, with presence of multiple air corpuscles from nasofrontal articulation to hard palates, frontal sinus, maxillary, sphenoidal and right anterior and posterior ethmoidal cells aerated and free, left papyraceous lamina slightly lysed, left orbit with anterior air corpuscles, periorbital muscles preserved, nasal septum with perforation of approximately 3 mm towards

Laboratory studies were taken upon admission, observing in his hematic biometry leukocytes 9.2, neutrophils 7.8, lymphocytes 0.92, hemoglobin 8.3, mean corpuscular volume 73.7, mean concentration of hemoglobin 22 and platelets of 611,000. Blood chemistry with glucose 141, BUN 6, creatinine 0.4, uric acid 2.4, total cholesterol 109 and triglycerides of 162. Serum electrolytes with calcium 7.3, phosphorus 2.63, magnesium 1.88, potassium 3.02 and sodium 140.5.

PCR was taken for SARS-COV 2 (COVID 19), resulting positive on 02/05/21.

Upon admission, a soft and hard palate culture was taken, which reported the presence of Klebsiella penumoniae and Staphylococcus aureus.

An imprint of the sample obtained from the soft and hard palate was also taken, which reported non-septate hyphae on light microscopy.

The patient was admitted to the Infectous diseases' service for antifungal management, as well as metabolic control of comorbidities, later, endoscopic functional surgery ("Full House" type) is performed with findings of necrotic scabs on the floor, left lateral wall and nasal roof, as well as obstruction of the recess of the frontal and ethmoid sphenoid, ostium of the maxilla by these, a fetid yellowish discharge is obtained during the procedure, it also had a 5x5 necrotic eschar mentioned above, which is resected, necrotic tissue is debrided and nasal bones are visualized and Upper and lower lateral cartilages with areas of necrosis which are removed, necrotic anterior ethmoidal artery is also visualized and all necrotic tissue is debrided until bleeding is obtained, in turn, necrotic eschar from the soft and hard palate is removed, observing communication with the nasal floor . The procedure was terminated without apparent complications and the patient continued her hospital stay in our service, as well as with joint management with Internal Medicine and Infectous diseases. (Figures 2 and 3). The tissue obtained in surgery was sent to pathology for analysis, finding non-septate hyphae with vascular invasion. (Figure 4).

After several washings and debridements, as well as treatment with amphotericin B, improvement of the infectious process was obtained. The wound is currently being granulated in order to make a flap and reconstruct the eyelid. It has periodic reassessments with the Ophthalmology service, who highlighted the need to start topical management with tobramycin and moxifloxacin as an antibiotic, as well as dexamethasone as a topical steroid. She received a cumulative dose of 12 g of amphotericin B.

DISCUSSION

The emergence of the COVID-19 has placed a great burden on health services around the world, and efforts are focused on treating this disease. Secondary infections are a recognized complication of respiratory virus infections.

The etiology of mucormycosis varies considerably in different countries, a new species of Apophysomyces: A. mexicanus, has been reported in Mexico.

The fungus enters the body by inhalation of sporangiospores, it's by angioinvasion or direct invasion of the paranasal sinuses how the CNS infection starts. Once the fungus enters, it's because of the alveolar macrophages and the neutrophils that the fungus can be annihilated, but, there are cases such as hypreglycemia, ketoacidosis and corticosteroid-treated patients that impairs its celular immunity against the fungus or even other agents.[5]

Its morphology consists of non-septate thick hyphae as it principal structure, it also has a right angle branching, this fungus shows tropism for the intima layer of the arteries, which favors the presentation of arteritis with microthrombi, later ischemia of the tissues, coagulative-hemorrhagic necrosis, endothelial damage, localized inflammation and gangrene. Once the hyphae invade the nasal mucosa, they move to the paranasal sinuses and from there to the orbit, eyeball and later the optic nerve.[6]

Within the mucorales, 3 microorganisms have been isolated mainly as the cause of most mucormycosis, being mainly Rhizopus in 70% of cases, Mucor and Absidia.[5]

70% of the cases of rhino-orbital-cerebral mucormycosis have been found in patients with diabetes mellitus. The infection usually presents with acute sinusitis, fever, nasal congestion, purulent nasal discharge, and headache.[7]

There is a significant association between patients with positive mycology and patients treated with high-dose steroids, this being one of the main treatments in severe COVID 19, which is associated with an increased risk of fungal or bacterial infections.[8]

Also, there's evidence of impairment of innate immunity due to COVID 19 and decrease in T cells and CD4 and CD8.[9]

On image studies the mucormycosis can be seen as a mucosal thickening, in magnetic resonance imaging it can be seen a non-enhancing mucosa tissue in sinuses and turbinates (Black turbinate sign) because of vessel occlusion and mucosal ischemia. There's also bony destruction in turbinate, sinus walls, orbital wall, skull base and hard palate. When the orbit is affected, it can be seen thickening and lateral displacement of the medial rectus muscle, preseptal edema, proptosis and orbital fat infiltration.

Diagnosis can be made with microbiological analyses of tissue obtained by biopsy or surgery. At microscopy it can be seen non-septate, broad hyphae with branching at right angle.

At fiberoptic examination of nasal cavity and septum, the mucous membranes are ischemic or even necrotic.

For treatment it's recommended debridement of infected tissue, antifungal treatment and correction of metabolic alterations or the leading cause of the patient's metabolic or immunologic alteration. As an antifungal treatment, amphotericin B in a dose of 5-10 mg/kg/day at IV administration is recommended. Duration of treatment should be at least of 28 days and may be up to 6 months.

In most cases, the infection is relentlessly progressive and leads to death unless treatment is promptly initiated with a combination of surgical debridement and antifungal therapy.[10]

CONCLUSION

Rhinoorbital mucormycosis is a rare disease which is common in patients with uncontrolled chronic noncommunicable diseases, malignancies and end-stage chronic kidney disease because of the immunosupresion of even by iron levels. Perhaps, during the COVID 19 pandemic, there has been reported at least 7 cases of mucormycosis associated with COVID 19. It can be because of the presence of diabetes mellitus, chronic kidney disease or malignancies and also it can be secondary to immunosupresion due to COVID 19 action on immunologic response. More studies are needed so we can find COVID 19 mixed with infections due to other agents and its impact on the patients' outcomes.

REFERENCES

1. Skiada, A., Lass-Floerl, C., Klimko, N., Ibrahim, A., Roilides, E., & Petrikkos, G. Challenges in the diagnosis and treatment of mucormycosis. Medical Mycology, 2018;56(suppl_1):S93–S101.
2. Wali U, Balkhair A, Al-Mujaini A. Cerebro-rhino orbital mucormycosis: An update. J Infect Public Health [Internet]. 2012;5(2):116–26.
3. Chennamchetty V K, Adimulapu S., Kola B P, Padua M D, Ambika C, Rao M V R, Post-COVID pulmonary mucormycosis- A case report. IP Indian J Immunol Respir Med 2021;6(1):62-66
4. White PL, Dhillon R, Cordey A, et al.: A national strategy to diagnose COVID-19 associated invasive fungal disease in the ICU. Clin Infect Dis. 2020, [Epub ahead of print]:ciaa1298. 10.1093/cid/ciaa1298
5. Chikley A, Ben-Ami R, Kontoyiannis DP. Mucormycosis of the central nervous system. J Fungi. 2019;5(3):1–20.
6. Prado-Calleros HM, Fajardo-Dolci G, Plowes-Hernández O, Jiménez-Gutiérrez C. Rhino-Orbital Mucormycosis. Cohort study of its treatment according disease extent and reversion of its pathophysiology. Gac Med Mex. 2016;152(6):770–82.
7. Werthman-Ehrenreich A: Mucormycosis with orbital compartment syndrome in a patient with COVID-19 . Am J Emerg Med. 2020, [Epub ahead of print]:10.1016/j.ajem.2020.09.032
8. J. M. Cisneros Herreros, G. Peñalva Moreno. Article in

ISSN (Online): 2565-4810; (Print): 2565-4802 | ICV 2019: 98.48 |

Press Article in Press. GEF Bull Biosci. 2010;1(1):1–6.
9. Sarkar, S., Gokhale, T., Choudhury, S. S., & Deb, A. K. COVID-19 and orbital mucormycosis. Indian Journal of Ophthalmology, 2021;69(4):1002–1004.
10. Spellberg, B., Edwards, J., & Ibrahim, A. Novel Perspectives on Mucormycosis: Pathophysiology, Presentation, and Management. Clinical Microbiology Reviews, 18(3), 556–569. doi:10.1128/cmr.18.3.556-569.2005

Source of Support: Nil; **Conflict of Interest:** None

Submitted: 02-06-2021; **Accepted:** 01-08-2021; **Published online**: 30-09-2021